CASE REPORT

Rare cause of superior vena cava syndrome: a giant bulla

Guntug Batihan, Ozan Usluer, Seyda Ors Kaya

Department of Thoracic Surgery, University of Health Sciences, Dr Suat Seren Chest Diseases and Surgery, Medical Practice and Research Center, Izmir, Turkey

Correspondence to
Dr Guntug Batihan, gbatihan@hotmail.com

Accepted 26 October 2018

SUMMARY

Superior vena cava syndrome (SVCS) is a group of symptoms caused by obstruction of superior vena cava. External compression caused by benign or malign processes is the most common physiopathology. We aim to present a 29-year-old man with non-productive cough, facial plethora and venous distention of the neck. Right apical tense bulla which was compress superior vena cava was detected and video-assisted thoracoscopic surgery applied. Our extensive search found out that only one report of SVCS secondary to bulla is available on Medline.

BACKGROUND

Superior vena cava syndrome (SVCS) is a group of symptoms caused by obstruction of SVC. The characteristic physical findings of SVCS include venous distention of the neck and chest wall, facial oedema, upper extremity oedema, mental changes, plethora, cyanosis, stupor, and even coma. More than 80% of cases of SVCS are caused by malignant tumours especially small-cell bronchogenic carcinomas.[1–3] Non-malignant conditions like mediastinal fibrosis, aortic aneurysm, benign mediastinal tumours, infections can also cause SVCS.[2–4] We present a rare case of SVCS caused by a tense bulla. To our knowledge, only one case has been reported previously.[5]

CASE PRESENTATION

A 29-year-old man admitted our clinic with 3-month history of non-productive cough and dyspnoea that aggravated with lying down. Examination of the patient revealed decreased breath sounds on auscultation of right upper lung field and facial plethora and venous distention of the neck was seen. The patient was a non-smoker and there was not any history of chronic illness, prior hospitalisation or surgery. His family history was also non-significant.

INVESTIGATIONS

Chest radiography revealed giant right apical bulla formation. CT revealed tense bullae in right hemithorax that cause SVC compression (figures 1 and 2A–C).

DIFFERENTIAL DIAGNOSIS

- Malignant tumours especially small-cell bronchogenic carcinomas.
- Benign mediastinal tumours.
- Aortic aneurysm.
- Pneumothorax.

TREATMENT

Video-assisted thoracoscopic surgery performed via two port. Right apical tense bulla was seen in exploration. The bulla measured 9×10×10 cm and connected to normal parenchyma with fibrous pedicle. Bullectomy was performed using endoscopic stapler. Routine haemorrhage and air leakage control was performed. One pleural catheter insert via camera port.

OUTCOME AND FOLLOW-UP

After surgery, the patient's facial plethora and cough disappeared. The postoperative course was

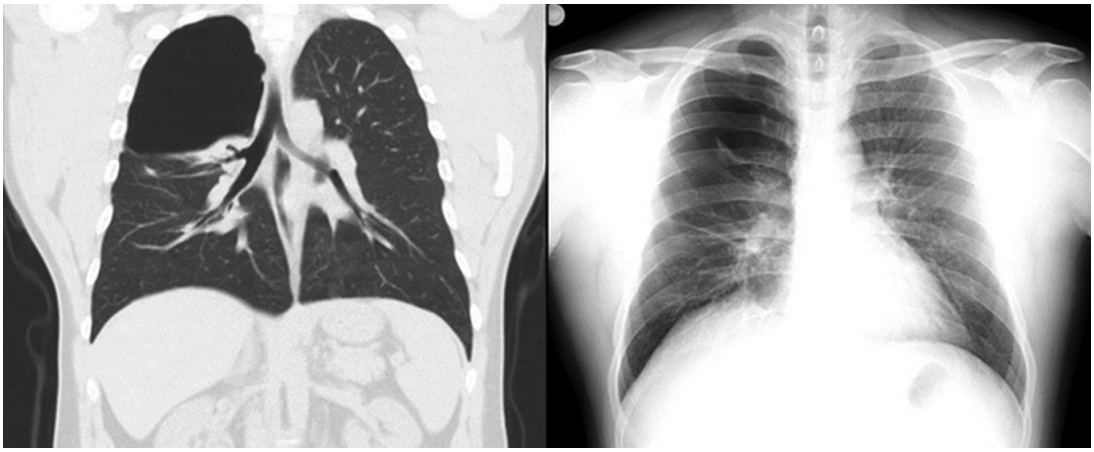

Figure 1 Preoperative CT and chest radiogram demonstrate right apical air filled space.

Check for updates

© BMJ Publishing Group Limited 2018. No commercial re-use. See rights and permissions. Published by BMJ.

To cite: Batihan G, Usluer O, Kaya SO. *BMJ Case Rep* 2018;**11**:e226477. doi:10.1136/bcr-2018-226477

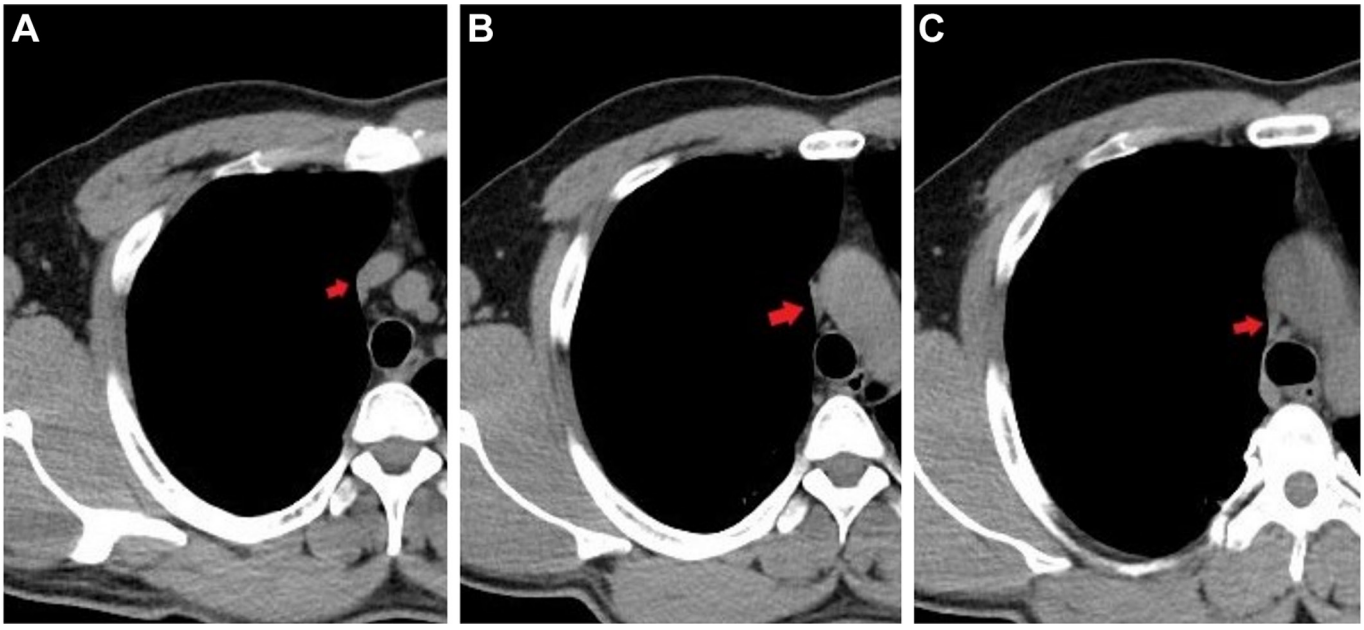

Figure 2 (A) Pre-operative CT (axial) superior vena cava (SVC) is formed by the union of the brachiocephalic veins (arrow). (B) Demonstrative figure of SVC compression by tense bulla (arrow shows compressed SVC). (C) Azygos vein enters the SVC (arrow). SVC is compressed above this level.

uneventful (figure 3). Chest tube was terminated at postoperative day 4.

DISCUSSION

SVCS is a group of symptoms caused by obstruction of SVC. More than 80% of cases of SVCS are caused by malignant mediastinal tumours.[1–3] Among the malignant causes, lung cancer is by far the most frequent cause, followed by lymphomas and metastasis or other tumours, breast cancer, germ cell tumours, sarcomas and so on.[6] External compression with or without invasion of the SVC represents the most common physiopathology in these cases. The most non-malignant cause of SVCS is intravascular devices (catheters and pacemakers, etc) related thrombus. With the increased use of these devices in recent years, thrombi associated SVCS has become much more common. The diagnosis of SVCS is made clinically with an accurate clinical history and physical examination, focusing on the duration and the speed of symptoms onset and the history of previous invasive procedures or malignant diseases. For grading SVCS and for select patients who are suitable for stent treatment, some classification schemes and scoring systems have been proposed based on the severity of the disease. Especially Kishi scoring system is important to select the suitable patient for stent treatment (table 1).[7] In this report, we have presented a rare case of SVCS caused by a tense bulla. In many case, emphysematous bullae tend to expand over time and make a comprassion and atelectasis in normal lung parenchyma. Sometimes severe pleural adhesion prevented the bulla from expanding and the pressure created by bulla effects mediastinal structures like SVC. As in our case SVC would be compressed by the effect of pressure created by tense

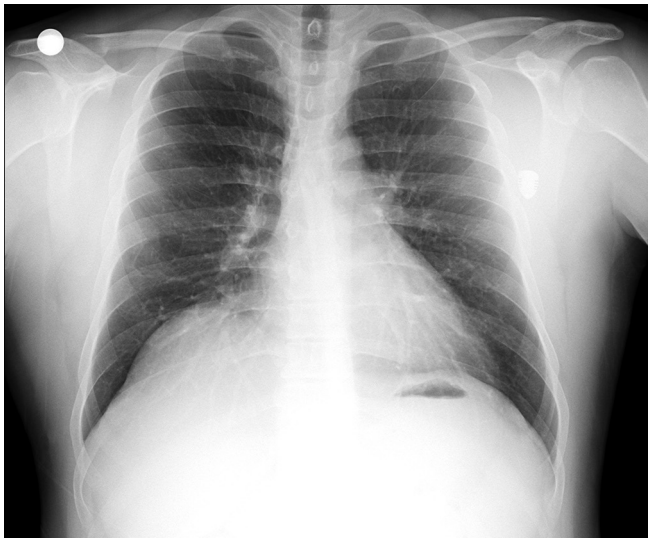

Figure 3 Postoperative chest radiogram.

Table 1 Percutaneous stent placement indicates when the score is 4 or higher

Clinical signs	
Neurological signs	
Awareness disorders or comas	4
Visual disorders, headache, vertigo or memory disorders	3
Mental disorders	2
Malaise	1
Thoracic or pharyngeal-laryngeal signs	
Orthopnoea or laryngeal oedema	3
Stridor, dysphagia, dyspnoea	2
Coughing or pleurisy	1
Facial signs	
Lip oedema, nasal obstruction or epistaxis	2
Facial oedema	1
Vessel dilation	
Neck, face or arms	1

bulla and thus causing SVCS. In this case, the patient only had coughing and facial oedema, therefore, stent treatment did not need.

Consequently in patients with right apical tense bullae, SVCS should be considered especially if clinical symptoms caused by SVC compression present.

Learning points

- Superior vena cava syndrome (SVCS) is a group of symptoms caused by obstruction of SVC.
- External compression of the SVC represents the most common physiopathology.
- Giant bulla in lung parenchyma can give symptoms in many ways but it is extraordinary cause of SVCS.
- Surgical resection of the bulla (bullectomy) is the main way to remove compression of the SVC and symptoms would rapidly disappeared after surgery.
- Video-assisted thoracoscopic surgery should be preferred in proper cases.

Contributors GB, OU and SOK designed the study, developed the methodology, collected the data, performed the analysis and wrote the manuscript.

Funding The authors have not declared a specific grant for this research from any funding agency in the public, commercial or not-for-profit sectors.

Competing interests None declared.

Patient consent Obtained.

Provenance and peer review Not commissioned; externally peer reviewed.

REFERENCES

1 Hunter W. The history of an aneurysm of the aorta with some remarks on aneurysms in general. *Med Obs Enq* 1757;1:323–57.
2 Schechter MM. The superior vena cava syndrome. *Am J Med Sci* 1954;227:46–56.
3 Flounders JA. superior vena cava syndrome. *Oncol Nurs Forum* 2003;30:E84–E90.
4 Ahmann FR. A reassessment of the clinical implications of the superior vena caval syndrome. *J Clin Oncol* 1984;2:961–9.
5 Nemoto T, Terada Y, Matsunobe S, *et al*. Superior vena cava syndrome caused by a right apical tense bulla. *Chest* 1994;105:611–2.
6 Straka C, Ying J, Kong FM, *et al*. Review of evolving etiologies, implications and treatment strategies for the superior vena cava syndrome. *Springerplus* 2016;5:1–13.
7 Kishi K, Sonomura T, Mitsuzane K, *et al*. Self-expandable metallic stent therapy for superior vena cava syndrome: clinical observations. *Radiology* 1993;189:531–5.

Copyright 2018 BMJ Publishing Group. All rights reserved. For permission to reuse any of this content visit
https://www.bmj.com/company/products-services/rights-and-licensing/permissions/
BMJ Case Report Fellows may re-use this article for personal use and teaching without any further permission.

Become a Fellow of BMJ Case Reports today and you can:
- Submit as many cases as you like
- Enjoy fast sympathetic peer review and rapid publication of accepted articles
- Access all the published articles
- Re-use any of the published material for personal use and teaching without further permission

For information on Institutional Fellowships contact consortiasales@bmjgroup.com

Visit casereports.bmj.com for more articles like this and to become a Fellow