CASE REPORT

Rare complication of central venous catheter placement: bilateral hydrothorax

Guntug Batihan, Kenan C Ceylan, Seyda Ors Kaya

Dr Suat Seren Chest Diseases and Surgery, Medical Practice and Research Center, Department of Thoracic Surgery, University of Health Sciences, Izmir, Turkey

Correspondence to
Dr Guntug Batihan, gbatihan@hotmail.com

Accepted 2 December 2018

SUMMARY

Central venous catheters (CVCs) are very useful tools in clinical medicine. It is important not only for the administration of medications or fluids but also the measurement of haemodynamic variables, especially in intensive care patients. CVC placement is a relatively safe procedure but may occasionally be associated with complications, such as pneumothorax, haemothorax, cardiac tamponade, sepsis and thrombosis. We aim to report an extraordinary case of bilateral hydrothorax due to CVC placement.

BACKGROUND

Central venous catheters (CVCs) are frequently used in intensive care patients.

It is a very useful tool to monitor patients' haemodynamic variables and the administration of fluids and medications; however, catheterisation may cause vital complications, such as pneumothorax, haemothorax, cardiac tamponade, sepsis and thrombosis.[1–4] The most reported mechanical complications are arterial malpuncture, mispositioning, haematoma and pneumothorax. These complications occur in 5%–19% of all cases.[1 2]

Hydrothorax caused by central venous catheterisation is a rare and life-threatening complication. Few cases of ipsilateral hydrothorax have been reported before, but in this article, we aim to report an extraordinary case of bilateral hydrothorax due to CVC replacement.[1–6]

Our extensive search found out that very few reports of bilateral hydrothorax secondary to CVC are available on Medline.[7–9]

CASE PRESENTATION

A 37-year-old man underwent a surgical operation for intracranial mass under general anaesthesia. Before the surgery, the central line was placed through the right internal jugular vein. Only the blood aspiration confirmed, ultrasound guide or manometry was not used. The surgical procedure was uneventful, and the patient was admitted to the intensive care unit for immediate postoperative care. There, the patient received some more fluid. At night, the patient suddenly became dyspnoeic with a fall in O_2 saturation. On auscultation, there was no air entry on the right side of the chest.

INVESTIGATIONS

Emergency X-ray of the chest showed massive pleural effusion on the right side and minimally effusion on the left (figure 1). After the occurrence of these kinds of respiratory symptoms and findings, medical treatment (oxygen and bronchodilator agents) was immediately given. With the help of medical agents, vital signs of the patient were stabilised and chest CT was obtained. The malposed catheter was seen in chest CT (figures 2 and 3). As a result, the patient was diagnosed as iatrogenic hydrothorax and chest tube drainage was planned.

DIFFERENTIAL DIAGNOSIS

- Haemothorax.
- Parapneumonic effusion.
- Chylothorax.
- Pleural effusions from congestive heart failure.

TREATMENT

Right-sided tube thoracostomy was performed and 3000 mL of clear, yellowish fluid was drained into the right thorax tube (figure 4). This amount equals the fluid the patient received through the central line. The patient's condition improved quickly after drainage and CVC was removed immediately.

OUTCOME AND FOLLOW-UP

The follow-up chest X-ray did not show any effusion on the right side, and stable, minimally left-sided pleural effusion (figure 5). During follow-up, there was no progression on the left side, so no surgical intervention was required. The patient was discharged on the seventh day with stable vitals.

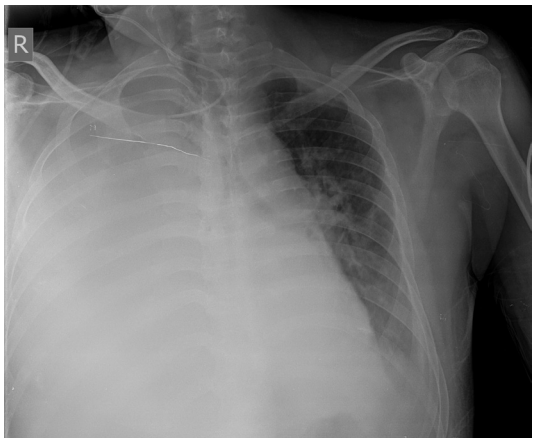

Figure 1 Plain chest radiograph taken in the early postoperative period showing the right lung that has been collapsed due to a large amount of right pleural effusion.

Check for updates

© BMJ Publishing Group Limited 2018. No commercial re-use. See rights and permissions. Published by BMJ.

To cite: Batihan G, Ceylan KC, Kaya SO. *BMJ Case Rep* 2018;**11**:e226699. doi:10.1136/bcr-2018-226699

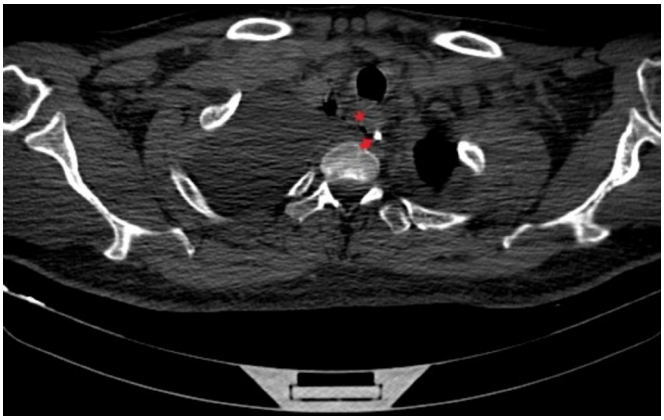

Figure 2 Catheter is observed between the oesophagus and the vertebral corpus, in the mediastinum outside the vessel. Asterisk indicates oesophagus, and the malposed catheter is marked with an arrow.

DISCUSSION

Central venous catheterisation is an essential procedure especially in the care of critically ill patients. It is a well-known and relatively safe procedure but sometimes is associated with acute complications during placement, such as pneumothorax, haemothorax, thrombosis, catheter-related infection and cardiac tamponade.

Hydrothorax is a rare complication of central venous catheterisation.[1–5] It can develop because of malposition or migration of catheter during placement and continuing the infusion of fluid. Mechanical trauma and chemical damage are thought to cause perforation.[7]

The incidence of catheter tip migration reported is about 17%, but this ratio is expected to be lower in experienced hands.[1–4]

There are some mechanisms defined in the literature for the complications of hydrothorax.

The first and generally accepted mechanism is the mechanical trauma caused by the angle that the catheter tip forms with the wall of a vein. There is a high risk of perforation when the tip of the catheter lies perpendicularly. Therefore, left-sided catheters have a high risk of perforation because of the anatomic location of the left innominate vein and superior vena cava (SVC).[10]

A second mechanism was described for the complication of hydrothorax. A wall erosion was caused by the traumatic effect of turbulent flow in the location where the azygos vein joins the SVC. Because of the turbulent flow, the tip of the catheter would erode the lateral wall of the SVC. This can lead to perforation of the vein and cause complication of hydrothorax.[11]

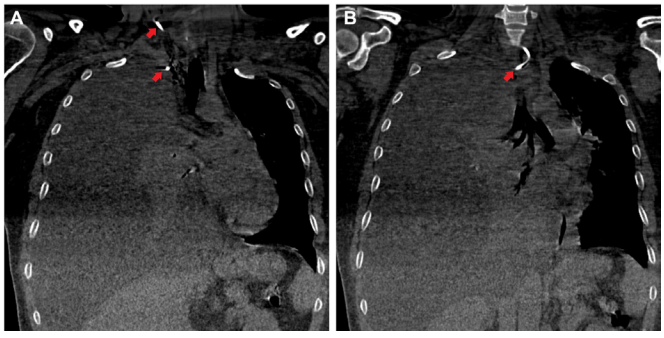

Figure 3 This coronal plane CT image shows the trace of the malposed central venous catheter. Arrows indicate the proximal and distal parts of the catheter in (A), and part of the catheter is which placed in between oesophagus and trachea is shown in (B).



Figure 4 A 2000 mL clear fluid was drained into the right thorax tube.

In this case, we think mechanical trauma would be the cause of malposition for two reasons. First, a wall erosion occurs because of the traumatic effect of turbulent flow or the chemical effect of fluid that was given to the patient. These two mechanisms need relatively more time to cause a perforation in the vessel wall. Second, catheter follows an inappropriate way in mediastinum seen in thorax CT (figure 3). This means the catheter perforated the vessel wall and passed outside of the vessel. As a result, in this case, mechanical trauma is likely to be the main cause of perforation.

As in our case, bilateral hydrothorax usually presents with a progressively worsening respiratory function and should



Figure 5 Chest X-ray after drainage of the right pleural effusion. A minimally pleural effusion is seen on the left side.

always be in the differential diagnosis of a rapidly progressive pleural effusion detected on chest X-ray. In our case, perioperative hypotension and low urine output resistant to the volume replacement and positive inotropic agents are significant signs of malfunction of the central venous line. Anyway this is a very rare complication, and it would be difficult to correlate this kind of non-specific findings to this complication. In contrast to many cases in the literature, where hydrothorax is unilateral, in our case hydrothorax was bilateral. Two mechanisms are responsible for this situation; first, mediastinal leaking, and second, direct intrapleural location. Because of the catheter's atypical course towards the contralateral lung, we think perforation of the mediastinal pleura is the main mechanism of contralateral hydrothorax.

It would be difficult to do diagnosis especially if the effusion is bilateral, but the clear fluid that was drained from the chest tube narrowed the differential diagnosis of the underlying pathology and thorax CT scan revealed malposition of the CVC.

We next provide some advice according to the literature and our clinical experiments to prevent these kinds of complications[12]:

Learning points

- Hydrothorax due to central venous catheter (CVC) placement is a rare but serious complication, and all healthcare professionals handling the CVC should be aware of these kinds of situations.
- In case of sudden change in the clinical situation of the patient after placement of CVC, like a sudden onset of severe dyspnoea, tachycardia and desaturation, a chest X-ray must be seen.
- As in our case, with the presence of hydrothorax or hydropneumothorax, catheter-related complications must borne in mind.
- Instead of CVC, peripheral vascular access should be used until definitive diagnosis is done.
- If the patient is diagnosed as catheter-related hydrothorax, tube thoracostomy must be performed and CVC must be removed.
- Vascular surgery should be consulted if vascular injury is suspected.
- It is not necessary to take a thorax CT, but it would be useful to prove malposition of CVC.
- Blood aspiration must be done through all ports and blood must flow smoothly into the syringe. It must be known that ultrasound-guided placement results in lower failure rates and reduced complications.
- A physician must take attention of the colour of the aspirated blood.
- If pressure transducer is present, the presence of venous waveforms must be confirmed.
- When there is a suspicion of migration, chest radiograph or thorax CT should be done.

Contributors GB has made a substantial contributions to the conception or design of the work; and interpretation of data. KCC has made a substantial contribution while final approval of the version to be published and conception and design ŞOK has made a substantial contribution while final approval of the version to be published.

Funding The authors have not declared a specific grant for this research from any funding agency in the public, commercial or not-for-profit sectors.

Competing interests None declared.

Patient consent for publication Obtained.

Provenance and peer review Not commissioned; externally peer reviewed.

REFERENCES

1 McGee DC, Gould MK. Preventing complications of central venous catheterization. *N Engl J Med Overseas Ed* 2003;348:1123–33.
2 Merrer J, De Jonghe B, Golliot F, *et al*. Complications of femoral and subclavian venous catheterization in critically ill patients: a randomized controlled trial. *JAMA* 2001;286:700–7.
3 Thomas CJ, Butler CS. Delayed pneumothorax and hydrothorax with central venous catheter migration. *Anaesthesia* 1999;54:987–90.
4 Krauss D, Schmidt GA. Cardiac tamponade and contralateral hemothorax after subclavian vein catheterization. *Chest* 1991;99:517–8.
5 Choi JG, Choi JS, Park CH, *et al*. Hydrothorax due to extravasation of intravenous contrast through left subclavian catheter -A case report-. *Korean J Anesthesiol* 2010;58:550–4.
6 Maroun R, Chalhoub M, Harris K. Right internal jugular venous cannulation complicated by tension hydrothorax. *Heart Lung* 2013;42:372–4.
7 Flatley ME, Schapira RM. Hydropneumomediastinum and bilateral hydropneumothorax as delayed complications of central venous catheterization. *Chest* 1993;103:1914–6.
8 Para RA, Mir AH, Kumar A, *et al*. Bilateral pleural effusion after central venous catheterization- a rare complication. *National J OF Med Research* 2015;5:329–31.
9 Ross P, Seashore JH. Bilateral hydrothorax complicating central venous catheterization in a child: case report. *J Pediatr Surg* 1989;24:263–4.
10 Fletcher SJ, Bodenham AR. Safe placement of central venous catheters: where should the tip of the catheter lie? *Br J Anaesth* 2000;85:298–302.
11 Booth SA, Norton B, Mulvey DA. Central venous catheterization and fatal cardiac tamponade. *Br J Anaesth* 2001;87:298–302.
12 Karnik PP, Shah HB, Dave NM. Garasia massive pleural effusion following central venous catheter migration: tips to remember. *Pediatric Anesthesia and Critical Care Journal* 2016;4:83–5.

Copyright 2018 BMJ Publishing Group. All rights reserved. For permission to reuse any of this content visit
https://www.bmj.com/company/products-services/rights-and-licensing/permissions/
BMJ Case Report Fellows may re-use this article for personal use and teaching without any further permission.

Become a Fellow of BMJ Case Reports today and you can:
- Submit as many cases as you like
- Enjoy fast sympathetic peer review and rapid publication of accepted articles
- Access all the published articles
- Re-use any of the published material for personal use and teaching without further permission

For information on Institutional Fellowships contact consortiasales@bmjgroup.com

Visit casereports.bmj.com for more articles like this and to become a Fellow