CASE REPORT

Atypical deep somatic soft-tissue leiomyoma of extrathoracic chest wall: first case of the literature

Guntug Batihan,[1] Ozan Usluer,[1] Seyda Ors Kaya,[1] Zekiye Aydogdu[2]

[1]Department of Thoracic Surgery, University of Health Sciences, Dr Suat Seren Chest Diseases and Surgery, Medical Practice and Research Center, Izmir, Turkey
[2]Department of Clinical Pathology, University of Health Sciences, Dr Suat Seren Chest Diseases and Surgery, Medical Practice and Research Center, Izmir, Turkey

Correspondence to
Dr Guntug Batihan,
gbatihan@hotmail.com

Accepted 18 November 2018

SUMMARY

Leiomyomas are benign soft-tissue tumours which take origin from the smooth muscles. Pleura and chest wall are uncommon location for such tumours. Here, we report a case of a 26-year-old female patient presented with 3 months history of chest pain. Chest X-ray and CT showed a calcified mass of 6×12 cm in size in the left lateral of the chest wall. After resection of the mass, pathological examination diagnosed it as atypical deep somatic soft-tissue leiomyoma of extrathoracic chest wall. No pathological finding was detected during follow-up.

BACKGROUND

Leiomyomas are benign tumours and they may occur in any body parts where smooth muscles are present but mostly in genitourinary and gastrointestinal tract.[1–3] Leiomyomas represent only 4.4% of benign tumours in soft-tissues and excluding those arising in cutaneous and subcutaneous tissue, leiomyomas in chest wall are very unusual.[1–6] All the cases of chest wall leiomyomas in literature report intrathoracic (intrapleural or extrapleural) localisation.[1–6] In our case, we report an unusual calcified atypical deep soft-tissue leiomyoma localisated in extrathoracic chest wall. To the best of our knowledge, this is the first case in the literature.

CASE PRESENTATION

A 26-year-old woman without any significant medical history was admitted to the hospital with 3 months history of chest pain and swelling in her left lateral chest wall. She was afebrile with a heart rate of 75, blood pressure of 125/75 mm Hg, respiratory rate of 16 and oxygen saturation of 95% on room air. On palpation, a deep-seated solid mass on the posterior axillary line was noted. The pain was continuous, unrelated to activity and exacerbated under palpation.

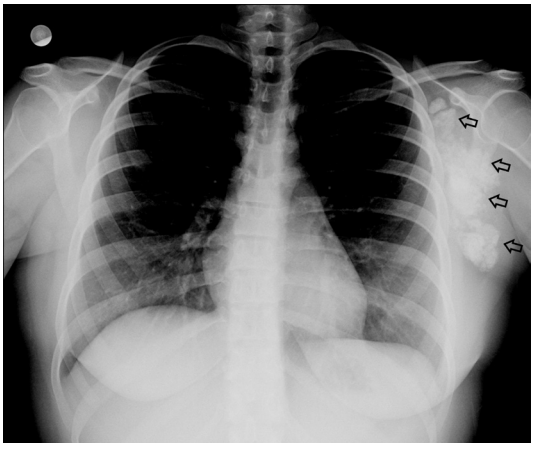

Figure 1 Chest radiogram demonstrating a heterogeneous radio-opacity in left lateral chest wall (arrows).

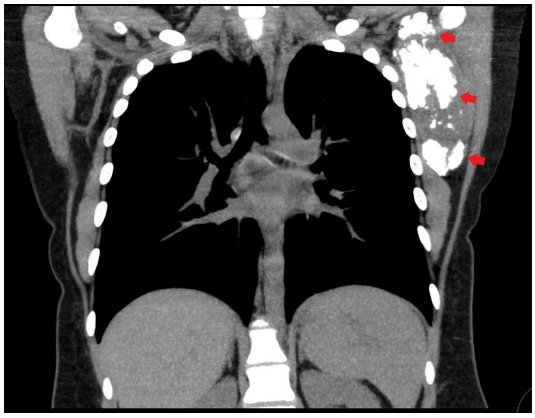

Figure 2 CT scan in coronal plane shows 6×12 cm calcified mass in left extrathoracic chest wall (arrows).

INVESTIGATIONS

Laboratory studies revealed normal haemoglobin (12.5 g/dL), white cell count (5.8×10^9/L) and platelet count(360×10^9/L). She had normal kidney and liver function. Chest radiogram revealed gross calcified mass located in left extrathoracic chest wall (figure 1). CT of the thorax revealed a 6×12 cm massive heterogeneously calcified gross mass located in left extrathoracic chest wall (figures 2 and 3). It was extend from the lower



Figure 3 CT scan in axial plane revealed calcified mass located between scapula and clavicula in lateral chest wall (arrow).

Check for updates

© BMJ Publishing Group Limited 2018. No commercial re-use. See rights and permissions. Published by BMJ.

To cite: Batihan G, Usluer O, Kaya SO, *et al*. *BMJ Case Rep* 2018;**11**:e226668. doi:10.1136/bcr-2018-226668



Figure 4 In lateral decubitus position, 4 cm incision was made from the level of lower scapula.

level of the scapula to the upper level. Fine needle or tru-cut biopsy is not preferred because of generalised calcification of the mass. So surgical excision was planned.

DIFFERENTIAL DIAGNOSIS

- Lipomas of the chest wall.
- Leiomyosarcoma of soft-tissue.
- Calcinosis.
- Calcified haematoma.

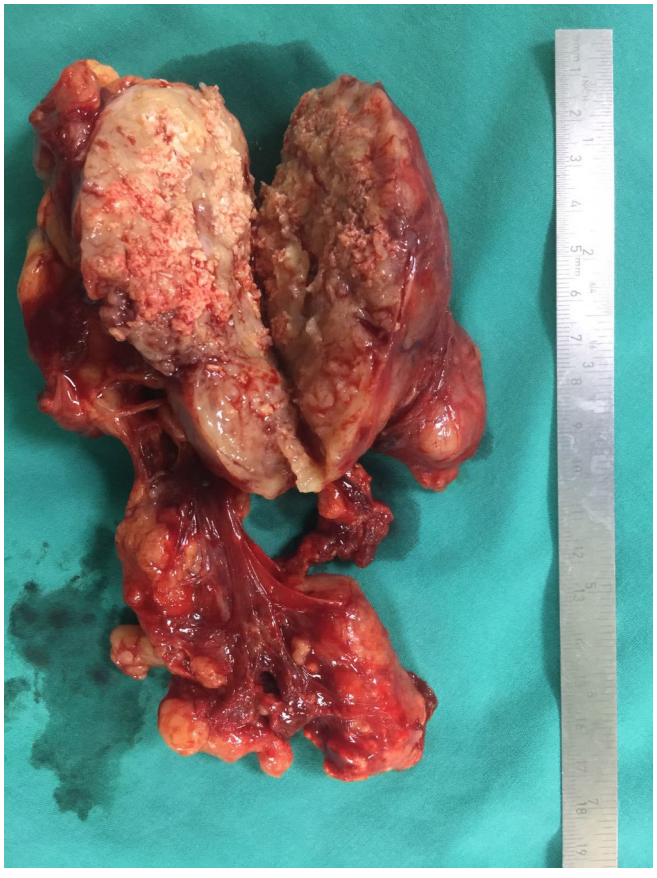

Figure 5 Complete resection with surrounding soft-tissue was performed.

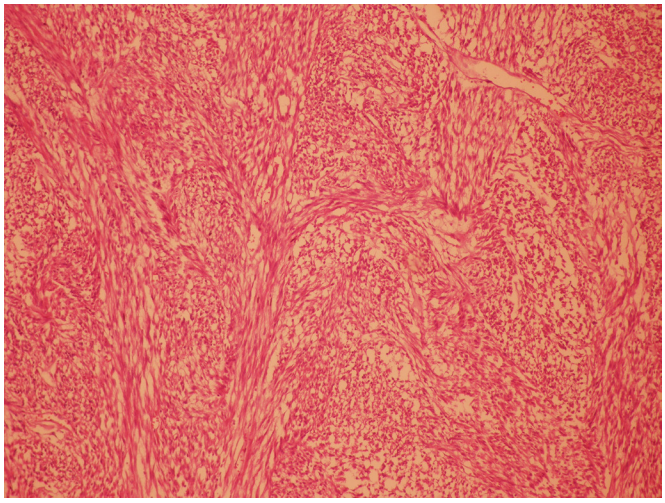

Figure 6 Classic microscopic findings of leiomyoma; fascicular pattern of smooth muscle bundles separated by well vascularised connective tissue with areas of calcifications. H&E x100.

TREATMENT

In lateral decubitus position, 4 cm incision was made from the level of lower scapula. After a diagnostic biopsy, complete resection with surrounding soft-tissue was performed (figures 4 and 5). The diagnosis of atypical leiomyoma of deep soft-tissue was rendered by histopathological findings (figures 6 and 7).

OUTCOME AND FOLLOW-UP

The postoperative course was uneventful and the patient was discharged on postoperative day 4. She was followed up regularly and there were no signs of recurrence 3 months after surgery (figure 8).

DISCUSSION

The definition of leiomyoma is described first in 1854 by Virchow and it was stated that these tumours originate from smooth muscles and occur in any part of the body.[4]

Leiomyomas are benign tumours and two histological types defined in literature as somatic soft-tissue and retroperitoneal.[1] These tumours mostly locate in uterus and commonly called a fibroid. Deep soft-tissue is uncommon localisation for leiomyomas and it is important to discriminate it from other malign soft-tissue tumours like leiomyosarcomas.[1–6] Some diagnostic criteria described in literature and some of them include absence of atypia, minimal to no mitotic activity and absence of necrosis.[7–10] But in a small part of leiomyomas focal or multifocal nuclear atypia would be seen and it was described in literature as 'atypical leiomyoma'.[9]

Pleura and chest wall are uncommon location for these tumours and only a few cases have been reported.[10] In chest wall smooth muscles would locate in beginning from the subpleural connective tissue of the parietal pleura, to the subdermal tissue so chest wall leiomyomas may originate from these structures.[4 5] Therefore, it is difficult to know exact origin of a leiomyoma in the thoracic wall. Many cases in the literature chest wall leiomyomas originated from pleura and the tumour growth into the thoracic space because the intrathoracic space provides the least tissue resistance. In the literature, there are few cases of intrapleural and extrapleural intrathoracic leiomyomas.[2–6 11] But in our case, leiomyoma was localisated in extrathoracic chest wall and surrounded with soft-tissue. So it is the first case of

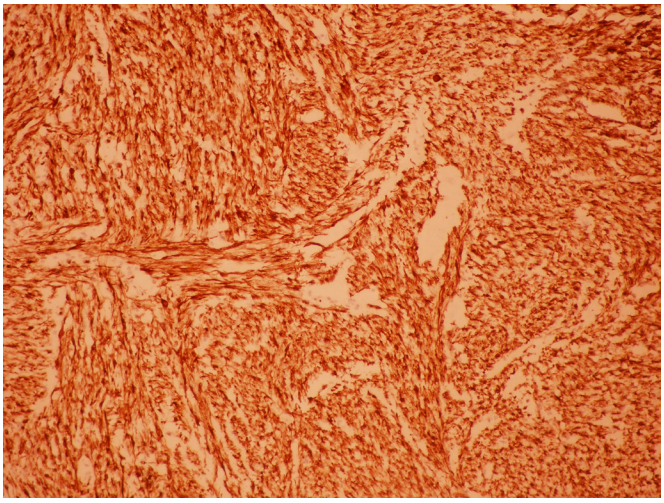

Figure 7 Fascicles of smooth muscle cells express smooth muscle actin immunostatin x200.

atypical deep somatic soft-tissue leiomyoma of extrathoracic chest wall in literature.

Surgical treatment should be chosen for a few reasons in these cases. First; benign tumours of the pleura or chest wall cannot be differentiated by radiological methods and the final diagnosis can only be established by histological examination. Second these tumours have possibility of degeneration into a malignant tumour (in literature it was defined as low but definite malignant potential) and finally, as in our case, patients usually have pain and swelling.[7] Because of all these reasons complete surgical excision is recommended.[2–8] The prognosis is good for patients whom complete surgical excision has done. The recurrence of chest wall leiomyoma is uncommon.[4–8]

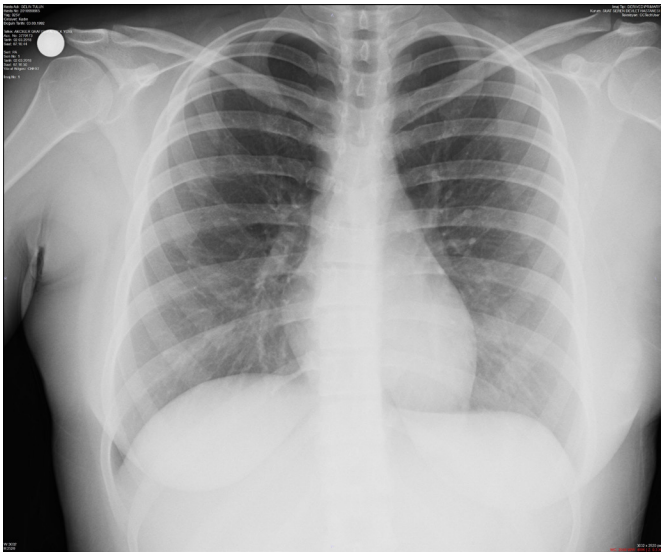

Figure 8 Postoperative chest radiograph after 3 months.

In conclusion, leiomyoma of deep soft-tissue should be considered in the differential diagnosis of any deep soft-tissue lesion that would be malign or benign. Surgery is the best choice to establishing the diagnosis and relieve symptoms.

We aim to report first case of atypical deep somatic soft-tissue leiomyoma of extrathoracic chest wall base on literature.

Learning points

- Leiomyomas are benign soft-tissue tumours that originate in the smooth muscles.
- Pleura and chest wall are uncommon location for such tumours.
- Many cases in the literature, chest wall leiomyomas originated from pleura and the tumour growth into the thoracic space.
- Surgery is the best choice to establishing the diagnosis and relieve symptoms.

Contributors GB, as a corresponding author, has a substantial contributions to the conception or design of the work; or the acquisition, analysis or interpretation of data for the work. OU has a substantial contribution while final approval of the version to be published and conception and design. SOK has a substantial contribution while discuss planning and final approval of the version to be published. ZA has a contribution in analysis and interpretation of data in field of pathology.

Funding The authors have not declared a specific grant for this research from any funding agency in the public, commercial or not-for-profit sectors.

Competing interests None declared.

Patient consent Obtained.

Provenance and peer review Not commissioned; externally peer reviewed.

REFERENCES

1 Billings SD, Folpe AL, Weiss SW. Do leiomyomas of deep soft tissue exist? An analysis of highly differentiated smooth muscle tumors of deep soft tissue supporting two distinct subtypes. *Am J Surg Pathol* 2001;25:1134e42.
2 Proca DM, Ross P, Pratt J, *et al*. Smooth muscle tumor of the pleura. A case report and review of the literature. *Arch Pathol Lab Med* 2000;124:1688–92.
3 Nose N, Inoue M, Kodate M, *et al*. Leiomyoma originating from the extrapleural tissue of the chest wall. *Jpn J Thorac Cardiovasc Surg* 2006;54:242–5.
4 Ziyade S, Ugurlucan M, Soysal O, *et al*. Leiomyoma of the extrapleural chest wall: an atypical location. *Arch Med Sci* 2011;7:356–60.
5 Yagci Tuncer L, Sulu E, *et al*. Primary Leiomyoma of The Chest Wall. *Solunum* 2011;13:191–3.
6 Kanlıoğlu Kuman N, Pabuşçu E, Meteoğlu I. Leiomyomas requiring chest wall resection and reconstruction. *Gen Thorac Cardiovasc Surg* 2014;62:186–90.
7 Qiu X, Zhu D, Wei S, *et al*. Primary Leiomyoma of the pleura. *World J Surg Oncol* 2011;9:76.
8 Mills AM, Ly A, Balzer BL, *et al*. Cell cycle regulatory markers in uterine atypical leiomyoma and leiomyosarcoma: immunohistochemical study of 68 cases with clinical follow-up. *Am J Surg Pathol* 2013;37:634–42.
9 Bertsch E, Qiang W, Zhang Q, *et al*. MED12 and HMGA2 mutations: two independent genetic events in uterine leiomyoma and leiomyosarcoma. *Mod Pathol* 2014;27:1144–53.
10 Fukunaga M, Ushigome S. Uterine bizarre lipoleiomyoma. *Pathol Int* 1998;48:562–5.
11 Turhan K, Cakan A, Cagirici U. Leiomyoma: an unusual pleural tumor: report of a case. *Turkish Respiratory Journal* 2008;9:53–5.

Copyright 2018 BMJ Publishing Group. All rights reserved. For permission to reuse any of this content visit
https://www.bmj.com/company/products-services/rights-and-licensing/permissions/
BMJ Case Report Fellows may re-use this article for personal use and teaching without any further permission.

Become a Fellow of BMJ Case Reports today and you can:
- Submit as many cases as you like
- Enjoy fast sympathetic peer review and rapid publication of accepted articles
- Access all the published articles
- Re-use any of the published material for personal use and teaching without further permission

For information on Institutional Fellowships contact consortiasales@bmjgroup.com

Visit casereports.bmj.com for more articles like this and to become a Fellow