Probiotics and Antimicrobial Proteins (2021) 13:375–382
https://doi.org/10.1007/s12602-020-09698-9

The Effects of Kefir on Kidney Tissues and Functions in Diabetic Rats

Mustafa Kahraman[1] · Yusuf Haydar Ertekin[2] · İlhan Satman[3]

Published online: 20 August 2020
© Springer Science+Business Media, LLC, part of Springer Nature 2020

Abstract
This study was designed to determine the protective effect of kefir on the oxidative damage, as well as histological and biochemical changes that occur in the kidney tissues of experimental diabetic rats. Forty rats were allocated into four groups as "healthy saline" (SF), "healthy kefir" (KF), and the same groups with experimentally induced diabetes (DSF and DKF). Diabetes was induced by administering 65 mg/kg single-dose streptozotocin. Oral kefir was given 10 ml/kg/day for 35 days to the rats in the groups KF and DKF. The same amount of saline was given to the groups SF and DSF. On the 36th day of the study, blood glucose, urea, and creatinine were measured besides glucose, creatinine, microalbuminuria, and sodium in the urine. Additionally, histological examination was performed on the kidney tissues. Blood glucose, creatinine, and urea levels were significantly lower in the DKF group compared with those of the DSF group ($p < 0.001$). Also, the creatinine level was significantly decreased ($p < 0.001$), and microalbuminuria was increased ($p < 0.001$) in the DKF group compared with that of the DSF group. Histologically, intermittent expansion in the renal glomeruli, reduction of cast formation in the tubules, and improvement in the renal epithelial tissues of the DKF group were observed. Kefir decreased the damage caused by diabetes. These results indicate that kefir supplementation may contribute to better control of oxidative stress, which is related to the improvement of renal functions, suggesting its use to slow down the progression of diabetic nephropathy.

Keywords Rats · Diabetic nephropathy · Streptozocin · Kefir · Reduction of oxidative stress · Diabetes mellitus · In vivo experiment

Introduction

Diabetes mellitus (DM) is a chronic metabolic disease characterized by hyperglycemia, dyslipidemia, glycosuria, and associated clinical and biochemical findings. Proteinuria, diffuse edema, hypertension, and glomerulotubular lesions associated with diabetic nephropathy are encountered in diabetic patients.

One of the most critical complications leading to end-stage renal disease is diabetic nephropathy [1]. Increasing evidence from both clinical and experimental studies has shown that there is a close link between hyperglycemia, oxidative stress, and diabetic complications [2]. High glucose activates reactive oxygen species, mitogenic protein kinases, and transcription factors, leading to mesangial cell growth. Various antioxidants contribute to improving the effects of diabetic nephropathy by inhibiting mesangial cell activation [3].

Complementary and alternative medicine (CAM) is getting popular among patients with DM. Almost one-quarter of patients with DM consume some kind of CAM during their disease [4]. Although systematic reviews could not support the routine use of CAM in DM, patients' demand for alternative is still important [5]. The inability of conventional medicine to meet patient needs, such as in chronic painful conditions [6] and cancer [7], might be a reason for this search. On the other hand, while some studies could not demonstrate the benefits of consuming probiotics for improving glucose control in diabetes [8], there are researchers [9] who claim a significant reduction in the

✉ Mustafa Kahraman
mkahraman17@gmail.com

Yusuf Haydar Ertekin
dr.ertekin@gmail.com

İlhan Satman
satmandiabet@gmail.com

[1] Istanbul School of Medicine, Department of Physiology, Istanbul University, Istanbul, Turkey

[2] School of Medicine, Department of Family Medicine, Çanakkale Onsekiz Mart University, Çanakkale, Turkey

[3] Istanbul Faculty of Medicine, Department of Internal Medicine, Division of Endocrinology and Metabolic Diseases, Istanbul University, Istanbul, Turkey

HbA1c levels with kefir consumption. Despite some conflicting reports on the benefits of probiotic fermented milk as an adjuvant in the treatment of diabetes [8, 9], a recent meta-analysis has suggested that probiotics may improve glycemic control and lipid metabolism in DM [10].

Kefir is a slightly foamy, whitish-colored, intensely stiff, and sour-tasted drink [11]. Kefir was first produced by fermenting milk from goats, sheep, cows, and other animals in the Caucasus mountains [12]. Kefir is quite different from other traditional dairy products like yogurt and fermented milk by its higher content of probiotic microorganisms, vitamin B complexes, and digestive enzymes [13]. It is also reported that diseases such as tuberculosis and digestive disorders are less common in areas where kefir is widely consumed. Furthermore, kefir shows antitumor, immunostimulant, antibacterial, antioxidant, and antidiabetic effects in animals [14].

In this study, we aimed to investigate the effects of kefir on diabetic nephropathy in experimental diabetic rats focusing on blood glucose levels and histological changes in the glomerular and tubular structures.

Materials and Methods

This study was conducted in 2014 with the approval of the Local Ethics Committee for Animal Experiments (date 13 February 2013 and approval number 2013/02-06) at the Experimental Studies Application and Research Center of Çanakkale Onsekiz Mart University.

Setting and Formation of the Experimental Groups

In this study, 64 male, six-week-old adult Sprague Dawley rats weighing 260–280 g, obtained from the Medicinal and Experimental Application and Research Center (COMUDAM) (Çanakkale, Turkey), were used. The rats were taken to a room with a temperature of 22 ± 2 °C, illuminated for 12 h of light and 12 h of darkness, 10 days before commencing the study. Fresh drinking water and pellet feed were given daily without any restrictions.

Of the 64 rats included, 48 were given streptozotocin (STZ) injections, while the remaining 16 were assigned to the control group. Because 23 of the 48 STZ-treated rats were excluded for various reasons, 25 rats remained in the experiment groups. Twelve out of the 23 rats were excluded from the study because their fasting blood glucose (FBG) was below 250 mg/dl, and 11 because they died within 24 h. Additionally, one of the 16 rats assigned to the control groups died, leaving 15 rats in the control group. Of the 25 rats with STZ-induced diabetes, 12 were randomly assigned to the saline-treated group (DSF) and 13 to the kefir-treated group (DCF), whereas of the 15 rats in the control group, 7 were assigned to the saline-treated group (SF) and 8 to the kefir-treated group (CF). As a result, the study was performed with 40 rats allocated into four groups (Fig. 1).

Experimental Diabetes Induction and Interventions

Rats in the DSF and DKF groups were injected intraperitoneally with 65 mg/kg streptozotocin (Sigma-Aldrich S0130, Merck KGaA, Darmstadt, Germany) dissolved in citrate buffer. After 72 h, blood was taken from the tail veins of the rats in both groups, and FBG was measured with a hand-held glucometer (Bayer Contour TS®, Istanbul, Turkey). Rats with FBG values of ≥ 250 mg/dl were considered diabetic and included in the study. On the same day, 10 ml/kg kefir (Radoha Kefir®, Secen Natural Food Co., Ltd., Bursa, Turkey) was initiated to the KF and DKF groups by oral gavage. The SF and DSF groups received 10 ml/kg saline [15]. The day starting kefir was set as the first day of the experiment. Rats in the DSF and DKF groups were given 1–3 units of insulin (Novorapid Penfill® 3 ml, Novo Nordisk, Bagsvaerd, Denmark) daily to prevent dying of ketoacidosis caused by hyperglycemia [16]. On the night of the 35th day, all groups were fasted and prepared for decapitation on the 36th day. The animals were anesthetized with 1.5 g/kg urethane (Sigma-Aldrich U2500, Merck KGaA, Darmstadt, Germany) before sacrification [17].

Characteristics of Kefir

A commercially available Turkish kefir grain (Radoha Kefir® Secen Natural Food Co., Ltd., Bursa, Turkey) was used. The kefir batches were prepared using 5% added kefir grains. The most abundant genus in the kefir product was *Lactobacillus*, containing dominant species such as *Lactobacillus kefiranofaciens*, *Lactobacillus buchneri*, *Lactobacillus helveticus*, *Lactobacillus casei*, and *Streptococcus thermophiles*. The producing company reported lactobacilli at levels of 108 CFU/ml after fermentation for 24 h. Samples stored at 5 ± 1 °C were used 7 to 14 days after production. It was reported that the most abundant genus with a mapped abundance of > 90% in Turkish kefir is *Lactobacillus* [18].

Biochemical Methods

On the 35th day of the study, the rats were placed in metabolic cages, and urine was collected for 24 h. On the 36th day (the last day of the experiment), the urine amount of the rats was measured, and urine glucose, creatinine, sodium, and microalbumin were assessed from the urine samples with a Roche Cobas 6000 analyzer (Roche Diagnostics, Basel, Switzerland). On the same day, intracardiac blood samples were collected into tubes containing anticoagulant and centrifuged at 4000 rpm for 10 min (Hettich Universal 320 R, Bäch Switzerland) to separate the serum. Blood glucose, creatinine,

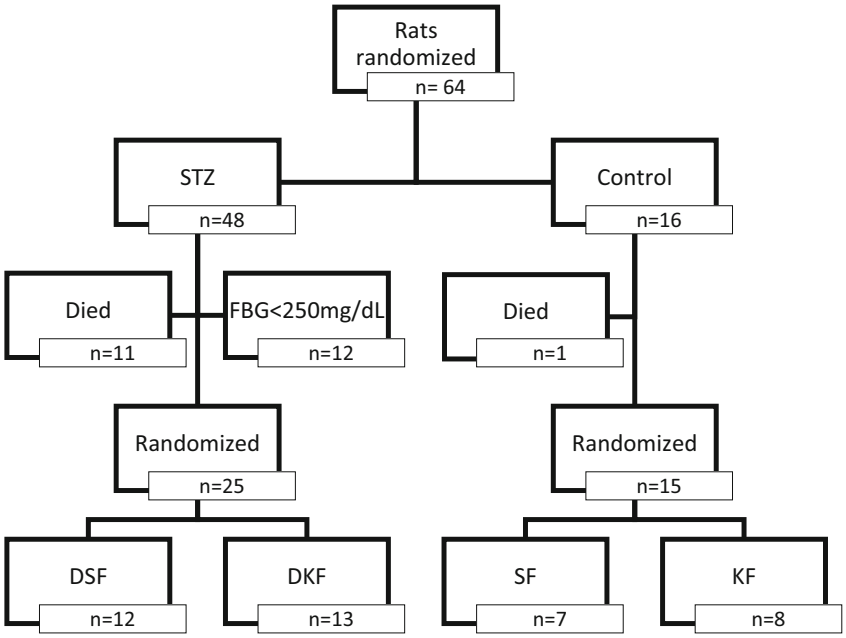

STZ: Streptozotocin. FBG: Fasting blood glucose. DSF: Saline-treated diabetic rats. DKF: Kefir-treated diabetic rats. SF: Saline-treated healthy rats. KF: Kefir-treated healthy rats.

Fig. 1 Study flow chart. *STZ*, streptozotocin; *FBG*, fasting blood glucose; *DSF*, saline-treated diabetic rats; *DKF*, kefir-treated diabetic rats; *SF*, saline-treated healthy rats; *KF*, kefir-treated healthy rats

urea, and sodium values were also determined by a Roche Cobas 6000 analyzer. The biochemical measurements were performed at the Çanakkale Onsekiz Mart University Research and Application Hospital Biochemistry Laboratory. Following decapitation, the right kidneys of the rats were removed. The tissues were preserved in a − 80 °C deepfreeze (Panasonic MDF-U5386S-PE, Osaka, Japan) until analysis.

Histological Methods

On the 36th day of the study, the right kidneys were removed with laparotomy. Tissues were analyzed for superoxide dismutase, catalase, glutathione, malondialdehyde, and myeloperoxidase.

The renal tissues were taken into 10% neutral formol fixative. Subsequently, histological tissue monitoring was performed manually. The paraffin-embedded kidney sections were subjected to Hematoxylin-Eosin (H-E) staining. Finally, the H-E-stained tissue samples were examined under a light microscope (Olympus Optical Co., Ltd., Tokyo, Japan), and histological pictures were taken as necessary.

Physiological Methods

The following formulas were used for Glomerular Filtration Rate (GFR), Fractional Sodium Excretion (FE_{Na}), and Fractional Water Excretion (FE_{Water}) calculations [19, 20]:

(a) $GFR = Ckr = (U_{Cr} \times V)/P_{Cr}$

GFR, Glomerular Filtration Rate; C_{Cr}, Creatinine clearance; U_{Cr}, Creatinine urine concentration; V, Urine volume; P_{Cr}, Creatinine plasma concentration [21]

(b) $FE_{Na} = (U_{Na} \times P_{Cr} \times 100)/P_{Na} \times U_{Cr}$

FE_{Na}, Fractional Sodium Excretion; U_{Na}, Sodium concentration in urine; P_{Na}, Sodium concentration in plasma; U_{Cr}, Creatinine concentration in urine; P_{Cr}, Creatinine concentration in plasma [21]

(c) $FE_{Water} = V/(U_{Cr} \times V/P_{Cr})$

FE_{Water}, Fractional Water Excretion; V, Urine volume; U_{Cr}, Creatinine concentration in urine; P_{Cr}, Creatinine concentration in plasma

Statistical Analysis

The GraphPad Prism 5.0 (La Jolla, California, USA) program was used for data analysis. Comparisons of the groups were made by the independent and paired *t* tests. Normal distribution of the numerical data was checked by the Shapiro-Wilk's test. Categorical data were presented as numbers and

percentages, while numerical variables were shown as "mean ± standard error."

Results

Biochemical Results

Compared with day 1, the FBG levels on day 36 were significantly higher in the KF group and significantly lower in the DKF group. The FBG levels on day 1 and 36 of the study are given in Table 1. The biggest change was in the DKF group; a 36.3% decrease was observed in this group, whereas a 13.8% increase was seen in the KF group.

Blood creatinine and urea levels were significantly higher in the DSF group than in the SF group. On the other hand, blood creatinine and urea levels were significantly lower in the DKF group compared with those of the DSF group (Table 2).

While urine microalbumin was significantly higher in the DSF group than in the SF group, urine creatinine was lower. Also, urine microalbumin levels of the DKF group were substantially lower than in the DSF group, and urine creatinine was higher in the DKF group (Table 2).

Results of Antioxidant Parameters in the Kidney Tissues

The rats in the DSF group had lower levels of superoxide dismutase, catalase, glutathione, and myeloperoxidase than the rats in the SF group (Table 2). On the other hand, rats in the DKF group had higher levels of superoxide dismutase, catalase, and glutathione enzymes compared with those in the DSF group. However, there was no difference in the mean myeloperoxidase levels. Also, there was no significant difference in the malondialdehyde levels compared between the KF and DKF groups (Table 2).

Physiological Results

The proportions of fractional sodium and water excretion in the 36th day are given in Fig. 2. While the GFR levels of the rats in the DSF group were significantly lower than those in the SF group, FE_{Na} and FE_{Water} levels were significantly higher ($p < 0.05$) (Table 2 and Fig. 2). Although the GFR levels of the rats in the DKF group were higher than those in the DSF group, FE_{Na} and FE_{Water} levels were significantly lower ($p < 0.05$) (Table 2 and Fig. 2).

Histological Evaluation of the Kidney Tissues

Histologic examinations revealed healthy glomerular and tubular structures in the SF group kidney tissues (Fig. 3a). Additionally, we observed dilatation of the renal tubules and cast formation in the lumen, as well as dilatation of the glomerular space in the DSF group (Fig. 3b). On the other hand, in the DKF group, dilatation of the glomerular space in the renal tissues, together with a decrease in cast formation in the tubular structures and improved epithelial appearance, was observed (Fig. 3c).

Discussion

As a summary of our main findings, kefir decreased FBG, blood creatinine, blood urea, urine glucose, microalbumin, and creatinine excretion in diabetic rats. It has been shown in previous studies that kefir and similar fermented products containing probiotics such as yogurt and dahi reduce blood glucose levels [22–24]. Aside from these studies, we found that variables directly related to the decrease in blood glucose, such as urea, creatinine, and urine glucose, have also decreased. The association between these variables suggests that kefir not only reduces blood glucose in diabetes but also protects the kidney functions by reducing urea and creatinine. On the other hand, these substances are uremic toxins, which increase as a result of the complications of diabetes in the kidneys.

Similar to our study, Punaro et al. investigated the antidiabetic effects of kefir. They induced experimental diabetes with streptozotocin in rats and gave kefir as a supplement. They looked at blood and urine creatinine levels in their study and found no significant differences in blood and urine creatinine between the diabetic controls and the study group [25]. On the contrary, our findings were significant. Although the

Table 1 Fasting glucose levels of rats at day 1 and day 26

	Day 1 (mean ± SD)	Day 36 (mean ± SD)	*t*	*p*
SF (mg/dl) $n = 7$	169.60 ± 8.11	170.36 ± 12.92	0.131	0.897
KF (mg/dl) $n = 8$	144.23 ± 8.18	164.27 ± 12.62	3.768	0.002
DSF (mg/dl) $n = 12$	547.56 ± 26.45	564.56 ± 40.32	1.212	0.234
DKF (mg/dl) $n = 13$	513.19 ± 23.43	326.90 ± 54.09	11.394	<0.001

SF, saline-treated healthy rats; *KF*, kefir-treated healthy rats; *DSF*, saline-treated diabetic rats, *DKF*, kefir-treated diabetic rats

Table 2 Glucose and kidney function measurements

	Control		Diabetes				
	SF ($n = 7$)	KF ($n = 8$)	DSF ($n = 12$)	DKF ($n = 13$)	t; p*	t; p**	t; p***
Fasting blood glucose (mg/dl)	170.35 ± 12.22	164.29 ± 12.64	564.57 ± 40.36	326.98 ± 54.68	9.432; < 0.001	− 7.221; < 0.001	24.916; < 0.001
Urinary glucose (mg/dl)	9.81 ± 3.02	9.87 ± 3.12	1141.12 ± 7.18	1009.02 ± 87.09	4.019; < 0.001	− 28.265; < 0.001	393.318; < 0.001
Blood creatinine (mg/dl)	0.26 ± 0.01	0.30 ± 0.03	0.51 ± 0.02	0.43 ± 0.02	7.679; < 0.001	− 10.535; < 0.001	30.651; < 0.001
Blood urea (mg/dl)	38.51 ± 2.05	40.09 ± 1.08	137.96 ± 14.59	90.38 ± 12.08	6.848; < 0.001	− 10.237; < 0.001	17.722; < 0.001
Urine microalbumin (mg/dl)	6.60 ± 1.04	7.89 ± 0.66	20.22 ± 4.32	10.27 ± 1.18	6.149; < 0.001	− 4.571; < 0.001	8.114; < 0.001
Urine creatinine (mg/dl)	94.15 ± 15.07	88.38 ± 7.65	27.56 ± 2.08	52.96 ± 9.09	− 7.255; < 0.001	8.079; < 0.001	− 15.373; < 0.001
Glomerular filtration rate (ml/min/100 g)	0.65 ± 0.05	0.59 ± 0.02	0.32 ± 0.04	0.47 ± 0.04	− 7.200; < 0.001	6.907; < 0.001	− 15.845; < 0.001
Kidney tissue superoxide dismutase (U/mg)	4.45 ± 0.15	4.87 ± 0.11	2.96 ± 0.16	4.13 ± 0.06	− 18.902; < 0.001	17.666; < 0.001	− 20.013; < 0.001
Kidney tissue catalase levels (U/mg)	4.95 ± 1.97	5.52 ± 0.63	0.79 ± 0.16	2.29 ± 0.26	− 13.212; < 0.001	14.556; < 0.001	− 7.429; < 0.001
Kidney tissue glutathione (U/mg)	0.80 ± 0.09	1.04 ± 0.26	0.13 ± 0.02	0.59 ± 0.05	− 22.836; < 0.001	5.416; < 0.001	− 25.230; < 0.001
Kidney tissue myeloperoxidase (mmol/mg)	0.43 ± 0.08	0.41 ± 0.01	0.22 ± 0.05	0.18 ± 0.04	1.704; 0.101	13.920; < 0.001	− 7.092; < 0.001
Kidney tissue malondialdehyde (mmol/mg)	4.88 ± 0.67	4.65 ± 0.68	13.69 ± 1.02	5.09 ± 0.12	23.232; < 0.001	− 2.034; 0.056	20.313; < 0.001

SF, saline-treated healthy rats; *KF*, kefir-treated healthy rats; *DSF*, saline-treated diabetic rats; *DKF*, kefir-treated diabetic rats

*DSF vs. DKF

**KF vs. DKF

***SF vs. DSF

experimental designs were similar, Punaro et al. used male Wistar rats. Besides, there might be differences in kefir quality. In contrast to our commercial kefir product, Punaro et al. prepared their own fermented product, which contained *Lactococcus lactis subsp*., *Leuconostoc sp*., *Streptococcus termophilus*, and *Lactobacillus sp*. On the other hand, they examined the animals for blood and urine urea levels and found a substantial difference between the control group and the kefir-treated group. They reported similar blood and urine urea levels in the kefir and control groups. In our study, kefir did not prevent the excretion of microalbumin, which is an indicator of renal damage, but decreased its level.

Few studies have investigated the antidiabetic effects of microorganisms present in kefir and suggested that probiotic treatment can reduce blood glucose levels in diabetes [24–26]. The mechanisms by which probiotic bacteria modulate hyperglycemia are not fully understood. However, some explanations have been proposed. Probiotics may impel gut bacteria to produce insulinotropic polypeptides and glucagon-like peptide-l, which, in turn, may induce the uptake of glucose by muscles [9]. Additionally, the conversion of glucose into glycogen may be influenced by the liver [24]. Also, kefir may have shown its glucose-lowering effect via its antioxidant activity by several interacting pathways, which eventually are leading to blood sugar regulation or decreasing glucose absorption in the gastrointestinal tract [9].

Despite the studies favoring probiotics in the glycemic control of type 2 diabetic patients, there is also evidence suggesting the lack of such an effect. Tonucci et al. [27] and Moroti et al. [28] are among the researchers demonstrating the lack of benefits of probiotics in DM. However, the quality of studies investigating this issue was questioned, and more extensive trials were suggested to verify the benefits of probiotics and/or kefir on glycemic markers in patients with diabetes [8]. Oxidative stress may contribute to oxidative protein damage [29]. Markers of oxidative damage were significantly increased in diabetic patients having complications compared with those without complications [30]. It can be postulated that kefir may improve renal functions by reducing intraglomerular hypertension and oxidative stress caused by diabetes.

We found that kefir increased GFR and decreased FE_{Water} and sodium excretion in diabetic rats. The glomerular capillary endothelium, basal membrane, and podocytes are composed of layers. The main layer that provides filtration is the basal membrane. Glycosaminoglycans in the basal membrane are a class of strongly negatively charged proteins. Usually, proteins cannot pass through the second layer basal membrane because they are negatively charged [25]. This negative load is impaired in diabetes. Hence, renal function deteriorates, resulting in GFR changes. FE_{Na} and FE_{Water} disturbances occur in cases of functional tubular disorders and acute tubular necrosis [19]. On the other hand, kefir has been shown to

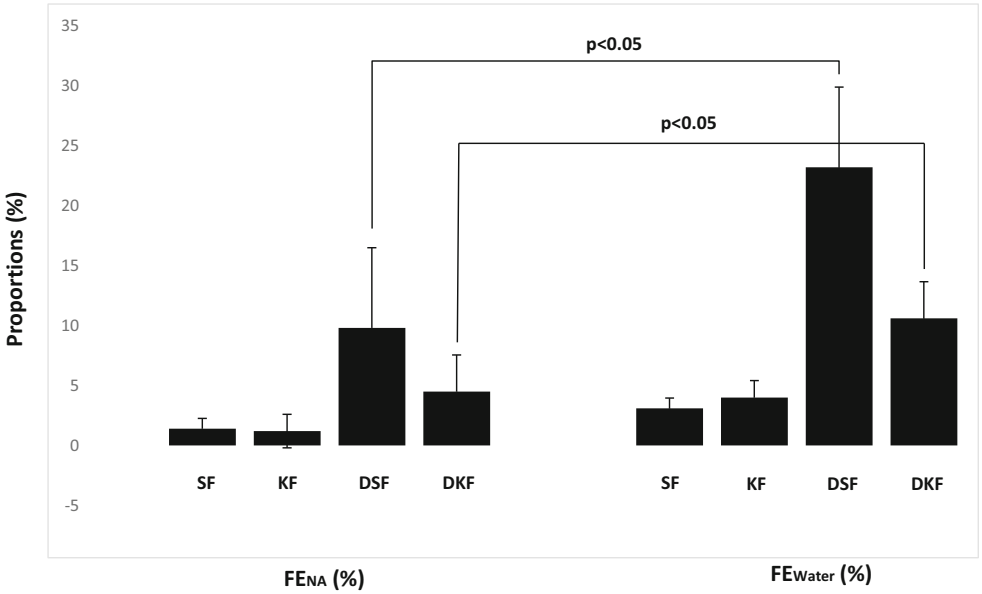

Fig. 2 Comparison of the fractional sodium and water excretion proportions between the groups. Error bars show standard deviations. SF, saline-treated healthy rats; *KF*, kefir-treated healthy rats; *DSF*, saline-treated diabetic rats; *DKF*, kefir-treated diabetic rats; FE_{Na}, Fractional Sodium Excretion; FE_{Water}, Fractional Water Excretion

Error bars show standard deviations. SF: Saline-treated healthy rats. KF: Kefir-treated healthy rats. DSF: Saline-treated diabetic rats. DKF: Kefir-treated diabetic rats. FE_{Na}: Fractional Sodium Excretion. FE_{Water}: Fractional Water Excretion.

decrease DNA fragmentation levels [15]. These data confirm that diabetes disrupts water and sodium reabsorption in the rat's kidney while suggesting that kefir has a preventive effect.

Biochemical analyses showed higher superoxide dismutase, catalase, and glutathione levels in the diabetic kefir group's renal tissues compared with those in the control group. In the study performed by Yadav et al. on diabetic rats, kefir's effect on the levels of superoxide dismutase, catalase, and glutathione in liver and pancreas tissues was similar to our study [31]. Hence, it may be claimed that kefir increases the antioxidant capacity of the tissues.

Another biochemical effect of kefir in the kidneys is the reduction of malondialdehyde levels. In our study, malondialdehyde, an indicator of tissue damage, was normal in the diabetic as well as the control group. It has been demonstrated in previous studies that kefir prevents tissue injury [25] and may reduce the incidence of pre-neoplastic lesions [31], which suggests that kefir may prevent tissue damage also in diabetes. However, myeloperoxidase levels, one of the antioxidant parameters in our study, were evaluated, and no difference was found between diabetic rat groups receiving or not receiving kefir.

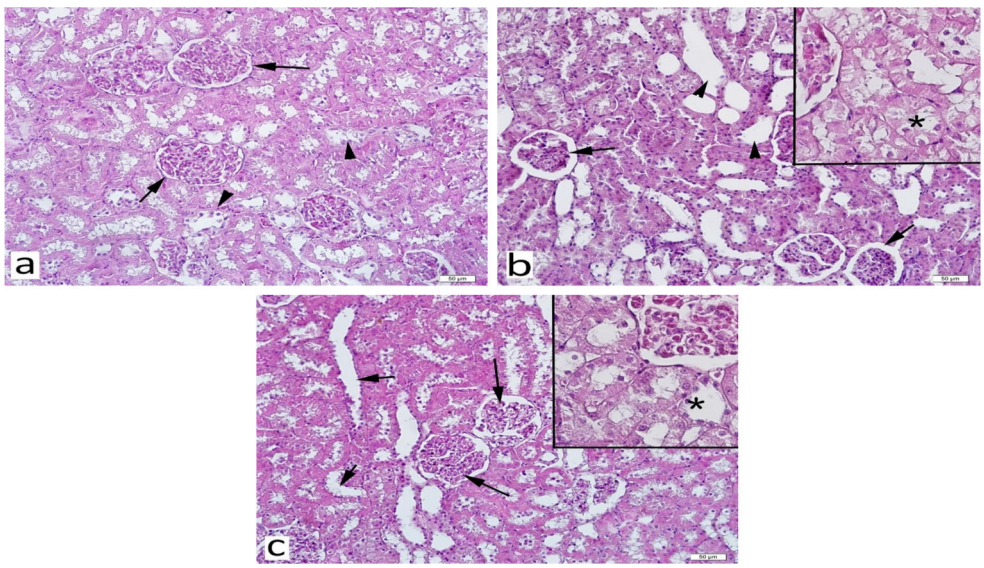

Fig. 3 Histologic examinations of the kidney tissues. **a** Healthy glomeruli (arrow) and tubular structures (arrowhead) in the saline-treated healthy rats (SF) group. **b** Saline-treated diabetic rats (DSF) group, enlargement of glomerular cavities (arrow), dilatation of tubular structures (arrowhead), cast formation in the tubular epithelium as well as shedding of epithelial cells (small picture *). **c** Kefir-treated diabetic rats (DKF) group, narrowing of glomerular cavities and improvement of tubular structures and epithelium (arrow), epithelialization of the tubule lumen (small picture *)

Concerning the histological examinations, compared with the DSF group, glomerular dilatation was similar in the DKF group, whereas tubular cast formation and epithelial damage were limited. In our study, dilation of glomerular space in the renal tissues, dilatation of renal tubules, and luminal cast formation were observed in diabetic rats. Kefir-treated diabetic rats continued to have enlarged glomerular space. However, cast formation in the tubular structures decreased, and epithelial appearance improved. Besides, the results of renal tissue histology and atrophy of renal tissues in the DSF and DKF groups are consistent with each other. Additionally, researchers have demonstrated that kefir has a histopathological preventive attribute on rats with rhabdomyolysis-induced acute renal failure [32]. Thus, we considered kefir having alleviating effects on the renal tissue damage produced by different mechanisms.

Conclusion

Kefir decreases blood glucose, creatinine, and urea levels in diabetic rats. It also reduces urinary glucose, microalbumin, and creatinine excretion. In diabetic rats, kefir increased GFR and decreased FE_{Water} and FE_{Na} excretion. Also, kefir increased superoxide dismutase, catalase, and glutathione levels; it decreased malondialdehyde levels but did not affect myeloperoxidase in the diabetic kidney tissue. Diabetes leads to an enlargement of glomerular space, tubule dilatation, and luminal cast formation in the kidney. However, kefir limited this cast formation and epithelial damage. Although further studies are needed to elucidate the exact mechanism behind its actions, we considered that kefir supplementation may contribute to better control of oxidative stress, which is related to the improvement of renal functions, suggesting its use as a supplement to slow down the progression of diabetic nephropathy.

Funding Information This study was supported by Çanakkale Onsekiz Mart University Scientific Research Projects Coordination Unit. Project Number: 2014-TYL-183.

Compliance with Ethical Standards

Conflict of Interest The authors declare that they have no conflict of interest.

References

1. Fava S, Hadjadj S, Walker J (2014) Diabetic renal disease. Int J Endocrinol 2014:1–2. https://doi.org/10.1155/2014/598015
2. Wu J, Mei C, Vlassara H, Striker GE, Zheng F (2009) Oxidative stress-induced JNK activation contributes to proinflammatory phenotype of aging diabetic mesangial cells. Am J Physiol Physiol 297: F1622–F1631. https://doi.org/10.1152/ajprenal.00078.2009
3. Ha H, Lee HB (2001) Oxidative stress in diabetic nephropathy: basic and clinical information. Curr Diab Rep 1:282–287. https://doi.org/10.1007/s11892-001-0047-1
4. Hunt K, Ernst E (2010) Patients' use of CAM: results from the Health Survey for England 2005. Focus Altern Complement Ther 15:101–103. https://doi.org/10.1211/fact.15.2.0005
5. Posadzki P, Lee MS, Ernst E (2012) Complementary and alternative medicine for diabetes mellitus: an overview of systematic reviews. Focus Altern Complement Ther 17:142–148. https://doi.org/10.1111/j.2042-7166.2012.01159.x
6. Mahmoudian SA, Babai ME, Jafari M (2012) The reasons for and satisfaction from using acupuncture in Isfahan. J Isfahan Med Sch 29(166):2280–2288 http://jims.mui.ac.ir/index.php/jims/article/download/1417/1838 Accessed 06 August 2020
7. Chiu L, Balneaves L, Barroetavena MC, Doll R, Leis A (2006) Use of complementary and alternative medicine by Chinese individuals living with cancer in British Columbia. J Complement Integr Med 3(1). https://doi.org/10.2202/1553-3840.1037
8. Barengolts E, Smith ED, Reutrakul S, Tonucci L, Anothaisintawee T (2019) The effect of probiotic yogurt on glycemic control in type 2 diabetes or obesity: a meta-analysis of nine randomized controlled trials. Nutrients 11(3):671. https://doi.org/10.3390/nu11030671
9. Ostadrahimi A, Taghizadeh A, Mobasseri M, Farrin N, Payahoo L, Beyramalipoor Gheshlaghi Z, Vahedjabbari M (2015) Effect of probiotic fermented milk (kefir) on glycemic control and lipid profile in type 2 diabetic patients: a randomized double-blind placebo-controlled clinical trial. Iran J Public Health 44(2):228–237 https://www.ncbi.nlm.nih.gov/pmc/articles/PMC4401881/
10. Li C, Li X, Han H, Cui H, Peng M, Wang G, Wang Z (2016) Effect of probiotics on metabolic profiles in type 2 diabetes mellitus: a meta-analysis of randomized, controlled trials. Medicine (Baltimore) 95(26):e4088. https://doi.org/10.1097/MD.0000000000004088
11. Hui YH, Meunier-Goddik L, Josephsen J, Nip W-K, Stanfield PS (2004) Handbook of food and beverage fermentation technology. CRC Press, Boca Raton. https://doi.org/10.1201/9780203913550
12. Kabak B, Dobson ADW (2011) An introduction to the traditional fermented foods and beverages of Turkey. Crit Rev Food Sci Nutr 51(3):248–260. https://doi.org/10.1080/10408390903569640
13. de Oliveira Leite AM, Miguel MAL, Peixoto RS, Rosado AS, Silva JT, Paschoalin VMF (2013) Microbiological, technological and therapeutic properties of kefir: a natural probiotic beverage. Braz J Microbiol 44(2):341–349. https://doi.org/10.1590/S1517-83822013000200001
14. Farnworth ERT (2003) Handbook of fermented functional foods. CRC press, Boca Raton. https://doi.org/10.1201/9781420053289
15. Kanbak G, Uzuner K, Kusat Ol K, Oglakci A, Kartkaya K, Senturk H (2014) Effect of kefir and low-dose aspirin on arterial blood pressure measurements and renal apoptosis in unhypertensive rats with 4 weeks salt diet. Clin Exp Hypertens 36(1):1–8. https://doi.org/10.3109/10641963.2013.783046
16. Osicka TM, Yu Y, Panagiotopoulos S, Clavant SP, Kiriazis Z, Pike RN, Pratt LM, Russo LM, Kemp BE, Comper WD, Jerums G (2000) Prevention of albuminuria by aminoguanidine or ramipril in streptozotocin-induced diabetic rats is associated with the normalization of glomerular protein kinase C. Diabetes 49(1):87–93. https://doi.org/10.2337/diabetes.49.1.87
17. Lang EJ, Tang T, Suh CY, Xiao J, Kotsurovskyy Y, Blenkinsop TA, Marshall SP, Sugihara I (2014) Modulation of Purkinje cell complex spike waveform by synchrony levels in the olivocerebellar system. Front Syst Neurosci 8. https://doi.org/10.3389/fnsys.2014.00210
18. Nalbantoglu U, Cakar A, Dogan H, Abaci N, Ustek D, Sayood K, Can H (2014) Metagenomic analysis of the microbial community in kefir grains. Food Microbiol 41:42–51. https://doi.org/10.1016/j.fm.2014.01.014

19. Hall JE, Guyton AC (2006) Textbook of medical physiology. Elsevier Health Sciences
20. Barrett KE, Barman SM, Boitano S, Brooks HL (2016) Ganong's review of medical physiology. McGraw Hill Education
21. Laiken ND, Fanestil DD (1985) Body fluids and renal function. In: West JB (ed) Best and Taylor's physiological basis of medical practice, 11th edn. Williams and Wilkins, Baltimore, pp 438–543
22. Yadav H, Jain S, Sinha PR (2008) Oral administration of dahi containing probiotic Lactobacillus acidophilus and Lactobacillus casei delayed the progression of streptozotocin-induced diabetes in rats. J Dairy Res 75(2):189–195. https://doi.org/10.1017/S0022029908003129
23. Hadisaputro S, Djokomoeljanto RR, Soesatyo MH (2012) The effects of oral plain kefir supplementation on proinflammatory cytokine properties of the hyperglycemia Wistar rats induced by streptozotocin. Acta Med Indones 44(2):100–104 https://pubmed.ncbi.nlm.nih.gov/22745139/
24. Al-Salami H, Butt G, Fawcett JP, Tucker IG, Golocorbin-Kon S, Mikov M (2008) Probiotic treatment reduces blood glucose levels and increases systemic absorption of gliclazide in diabetic rats. Eur J Drug Metab Pharmacokinet 33:101–106. https://doi.org/10.1007/BF03191026
25. Punaro GR, Maciel FR, Rodrigues AM, Rogero MM, Bogsan CSB, Oliveira MN, Ihara SSM, Araujo SRR, Sanches TRC, Andrade LC, Higa EMS (2014) Kefir administration reduced progression of renal injury in STZ-diabetic rats by lowering oxidative stress. Nitric Oxide 37:53–60. https://doi.org/10.1016/j.niox.2013.12.012
26. Lin C-H, Lin C-C, Shibu MA, Liu CS, Kuo CH, Tsai FJ, Tsai CH, Hsieh CH, Chen YH, Huang CY (2014) Oral Lactobacillus reuteri GMN-32 treatment reduces blood glucose concentrations and promotes cardiac function in rats with streptozotocin-induced diabetes mellitus. Br J Nutr 111(4):598–605. https://doi.org/10.1017/S0007114513002791
27. Tonucci LB, Dos Santos KMO, de Oliveira LL, Ribeiro SMR, Martino HSD (2017) Clinical application of probiotics in type 2 diabetes mellitus: a randomized, double-blind, placebo-controlled study. Clin Nutr 36(1):85–92. https://doi.org/10.1016/j.clnu.2015.11.011
28. Moroti C, Magri LFS, de Rezende CM, Cavallini DCU, Sivieri K (2012) Effect of the consumption of a new symbiotic shake on glycemia and cholesterol levels in elderly people with type 2 diabetes mellitus. Lipids Health Dis 11:29. https://doi.org/10.1186/1476-511X-11-29
29. Kayali R, Telci A, Cakatay U, Karaca C, Akcay T, Sivas A, Altug T (2003) Oxidative protein damage parameters in plasma in chronic experimental diabetes in rats. Eur J Med Res 8(7):307–312 https://pubmed.ncbi.nlm.nih.gov/12911868/
30. Cakatay U, Telci A, Salman S, Satman L, Sivas A (2000) Oxidative protein damage in type I diabetic patients with and without complications. Endocr Res 26(3):365–379. https://doi.org/10.3109/07435800009066174
31. dos Reis SA, da Conceição LL, e Dias MM et al (2019) Kefir reduces the incidence of pre-neoplastic lesions in an animal model for colorectal cancer. J Funct Foods 53:1. https://doi.org/10.1016/j.jff.2018.11.050
32. Karabacak P, Solmaz FA, Gultekin F et al (2016) The effectiveness of kefir in acute renal failure due to glycerol-induced rhabdomyolysis. Int J Clin Exp Med 9(9):17919–17925 http://www.ijcem.com/files/ijcem0027784.pdf Accessed 06 August 2020

Publisher's Note Springer Nature remains neutral with regard to jurisdictional claims in published maps and institutional affiliations.