The Egyptian Journal of Bronchology

CASE REPORT Open Access

Aspiration of a dental implant driver: a rare endobronchial foreign body successfully removed by uniportal VATS bronchotomy

Güntuğ Batıhan[1*], Muhammed Ziya Öcal[1], Hatice Çetin[1] and Timuçin Alar[1]

Abstract

Foreign body aspiration in adults is uncommon and often presents with vague, misleading symptoms, which may resemble infection, asthma, or malignancy. This diagnostic challenge can delay appropriate management. While most cases occur in children, adult aspiration is typically associated with neurological impairment, trauma, or iatrogenic events such as medical or dental procedures. Chest imaging and careful clinical history are crucial for diagnosis. Rigid bronchoscopy remains the gold standard for retrieval, but when the foreign body is firmly impacted, alternative strategies are required.

We describe a rare case of aspiration of a dental implant driver in a 40-year-old woman presenting with persistent cough and dyspnea. Radiology confirmed a metallic object lodged in the right lower lobe bronchus. Rigid bronchoscopy was attempted but unsuccessful due to the tight impaction. Uniportal video-assisted thoracoscopic surgery (VATS) was therefore performed. Intraoperative bronchoscopy guided a precise bronchotomy, allowing removal of the foreign body and primary closure of the bronchus. The patient's postoperative recovery was smooth, and she was discharged on the third day without complications.

This case highlights the role of uniportal VATS as a safe, minimally invasive alternative to thoracotomy when bronchoscopic extraction fails. The approach offers excellent visualization, facilitates precise bronchotomy, and reduces morbidity. Reports of dental implant components aspirated into the bronchial tree and managed with uniportal VATS are exceedingly rare. Our experience underscores the importance of considering uniportal VATS in selected adult patients, broadening the surgical armamentarium for complex foreign body aspirations.

Keywords Foreign body aspiration, Bronchus, Uniportal VATS, Bronchotomy, Dental implant

*Correspondence:
Güntuğ Batıhan
guntugbatihan@gmail.com
[1]Department of Thoracic Surgery, Faculty of Medicine, Çanakkale Onsekiz Mart University, Çanakkale, Türkiye

© The Author(s) 2026. **Open Access** This article is licensed under a Creative Commons Attribution 4.0 International License, which permits use, sharing, adaptation, distribution and reproduction in any medium or format, as long as you give appropriate credit to the original author(s) and the source, provide a link to the Creative Commons licence, and indicate if changes were made. The images or other third party material in this article are included in the article's Creative Commons licence, unless indicated otherwise in a credit line to the material. If material is not included in the article's Creative Commons licence and your intended use is not permitted by statutory regulation or exceeds the permitted use, you will need to obtain permission directly from the copyright holder. To view a copy of this licence, visit http://creativecommons.org/licenses/by/4.0/.

Introduction

Foreign body aspiration is an uncommon event in adults, in contrast to its higher prevalence in children. When it does occur, it is often associated with predisposing conditions such as neurological impairment, maxillofacial trauma, or iatrogenic complications during medical or dental procedures [1, 2]. Because clinical manifestations are frequently nonspecific—ranging from chronic cough and recurrent infections to unexplained dyspnea—diagnosis is easily delayed or mistaken for other respiratory diseases [3]. Imaging studies play a central role, but definitive management often depends on bronchoscopic evaluation.

Rigid bronchoscopy is the gold standard for foreign body retrieval; however, removal can be technically impossible when the object is firmly impacted in a distal airway. In such situations, surgical intervention becomes necessary [4, 5]. Traditionally, thoracotomy was the only option, but minimally invasive approaches such as video-assisted thoracoscopic surgery (VATS) now provide effective alternatives with reduced morbidity [6].

Uniportal VATS, in particular, has emerged as an innovative technique that combines excellent visualization with minimal surgical trauma. Although it is widely applied in anatomical resections and complex thoracic procedures, its role in the management of impacted airway foreign bodies remains rarely reported. We present a unique case of a dental implant driver aspirated into the right lower lobe bronchus, successfully retrieved via uniportal VATS after failed bronchoscopic extraction, and discuss its implications as a minimally invasive solution in selected adult patients.

Case presentation

A 40-year-old woman was admitted with a one-week history of persistent, irritating cough accompanied by new-onset exertional dyspnea. She denied fever, hemoptysis, or weight loss, and her past medical history was unremarkable. On auscultation, breath sounds were markedly diminished over the right lower lung field. Laboratory findings were within normal limits.

Chest radiography demonstrated an opaque shadow in the right lower zone (Fig. 1a), which was further characterized on computed tomography as a metallic foreign body lodged within the right lower lobe bronchus (Fig. 1b), associated with mild distal atelectasis. Upon detailed questioning, the patient recalled that a dental implant driver had accidentally fallen into her mouth during a dental procedure one week earlier. Believing it had been swallowed, no medical evaluation was sought at that time.

Flexible bronchoscopy confirmed the presence of the foreign body, and rigid bronchoscopy was subsequently attempted (Fig. 2a and b) (Video 1). However, the driver was tightly impacted in the segmental bronchus, making safe extraction impossible. Given the failure of

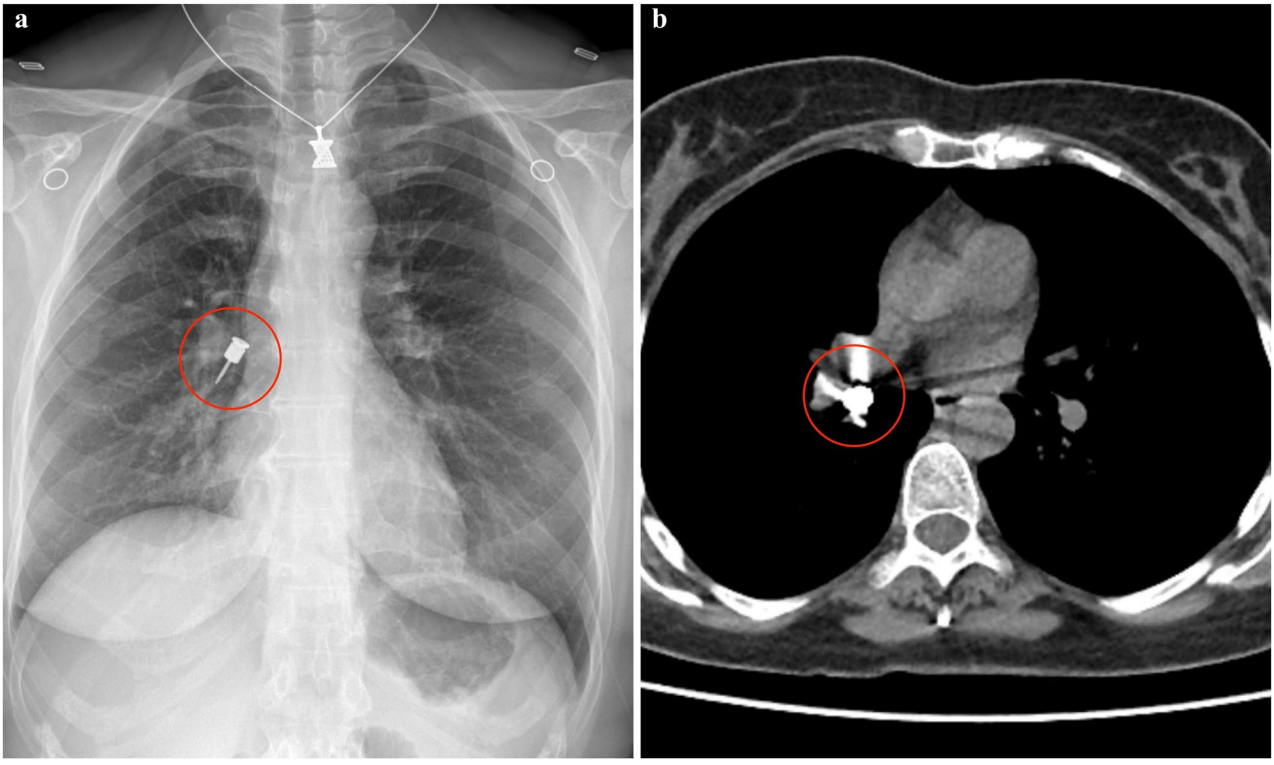

Fig. 1 **a** Posteroanterior chest radiograph of the patient. **b** Axial thoracic CT scan demonstrating the foreign body, indicated within the circle

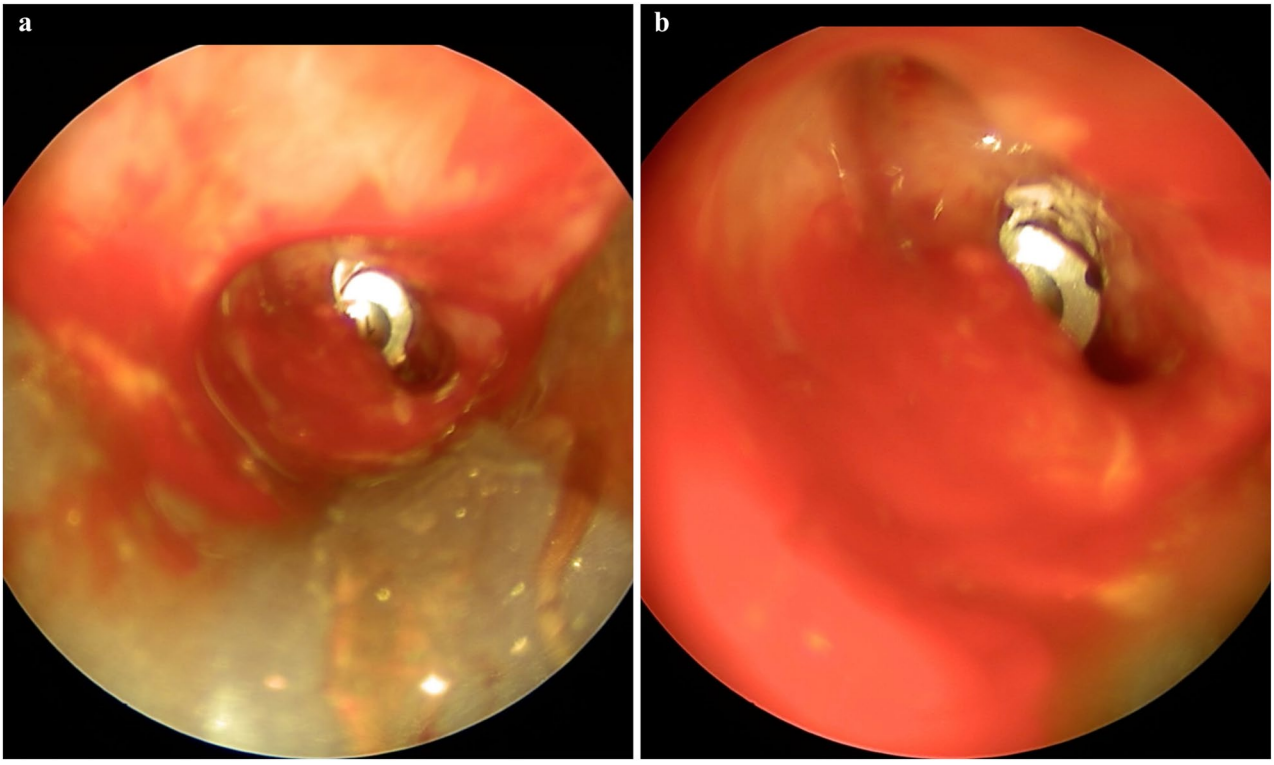

Fig. 2 Rigid bronchoscopy images demonstrating the foreign body within the right lower lobe bronchus (**a** and **b**)

endoscopic removal and the risk of prolonged obstruction and infection, the surgical team proceeded with uniportal right-sided video-assisted thoracoscopic surgery (VATS).

Surgical technique

The patient was placed in the left lateral decubitus position, and a 3-cm utility uniportal incision was created at the right 5th intercostal space along the mid-axillary line. After entering the pleural cavity, the lung was gently retracted anteriorly to expose the posterior hilum. The subcarinal space was carefully dissected, and the right main bronchus was skeletonized from proximal to distal until the basal segmental bronchi of the lower lobe were fully visualized.

To ensure precise localization of the foreign body, a thin flexible bronchoscope was advanced through the double-lumen endotracheal tube. The point of impaction was identified intraoperatively by transillumination of the bronchial wall (Fig. 3 and b). At the level of the right lower lobe bronchus, a vertical bronchotomy measuring approximately 1 cm was performed (Fig. 4a). The metallic dental implant driver was then retrieved using surgical forceps (Fig. 4b) (Video 2).

The bronchotomy was closed with interrupted non-absorbable 3 – 0 Prolene sutures to ensure durable bronchial wall approximation and to minimize the risk of postoperative air leak or early dehiscence under ventilatory stress (Fig. 4c and d). A water-seal test confirmed the absence of air leakage. Distal bronchial secretions, which had accumulated beyond the obstruction, were cleared under bronchoscopic guidance. Finally, a 24 F chest tube was placed through the uniportal incision, and the procedure was completed uneventfully.

The patient was extubated in the operating room and transferred to the ward in stable condition. Although no signs of diffuse airway inflammation or active infection were present, localized mucosal edema at the site of impaction limited bronchoscopic extraction. Prophylactic broad-spectrum antibiotics were administered due to the prolonged bronchial obstruction. The postoperative course was uneventful. No short-term complications, including prolonged air leak, pneumothorax, or surgical site infection, were observed. The chest tube was removed on postoperative day three, and the patient was discharged home in good condition.

Conclusions

This case highlights several key clinical considerations. Although foreign body aspiration is uncommon in adults, it should be suspected in patients presenting with unexplained respiratory symptoms and a relevant history, particularly following medical or dental procedures. Bronchoscopy remains the cornerstone of diagnosis and first-line management, and large clinical series have demonstrated its safety and effectiveness in a wide range

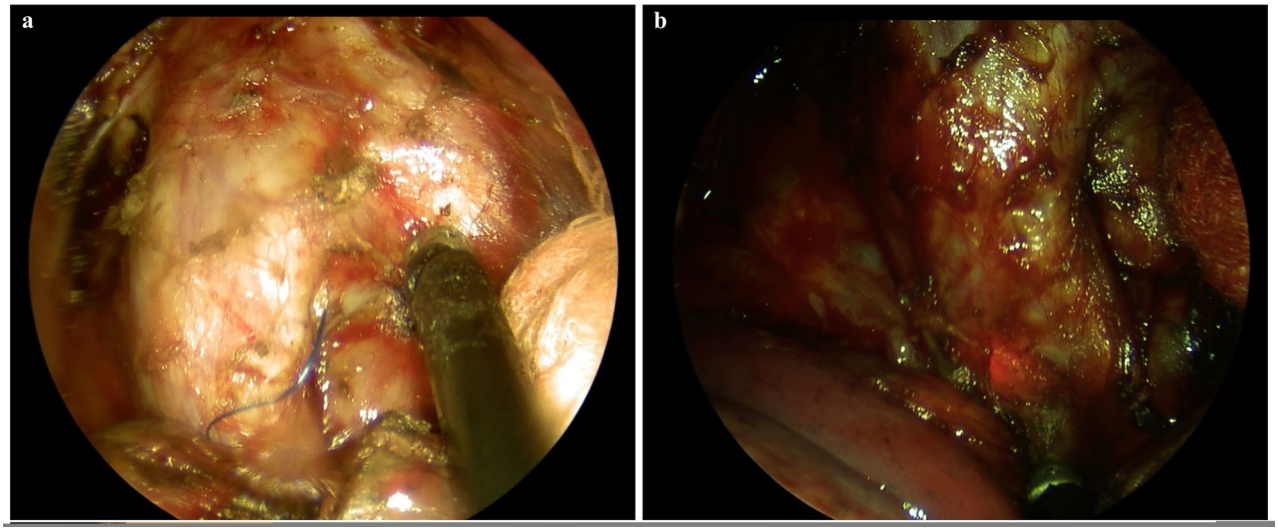

Fig. 3 **a** Division between the lower lobe and middle lobe bronchi. **b** With the thoracoscope light turned off, the illumination from the flexible bronchoscope is visible at the margin of the lower lobe bronchus

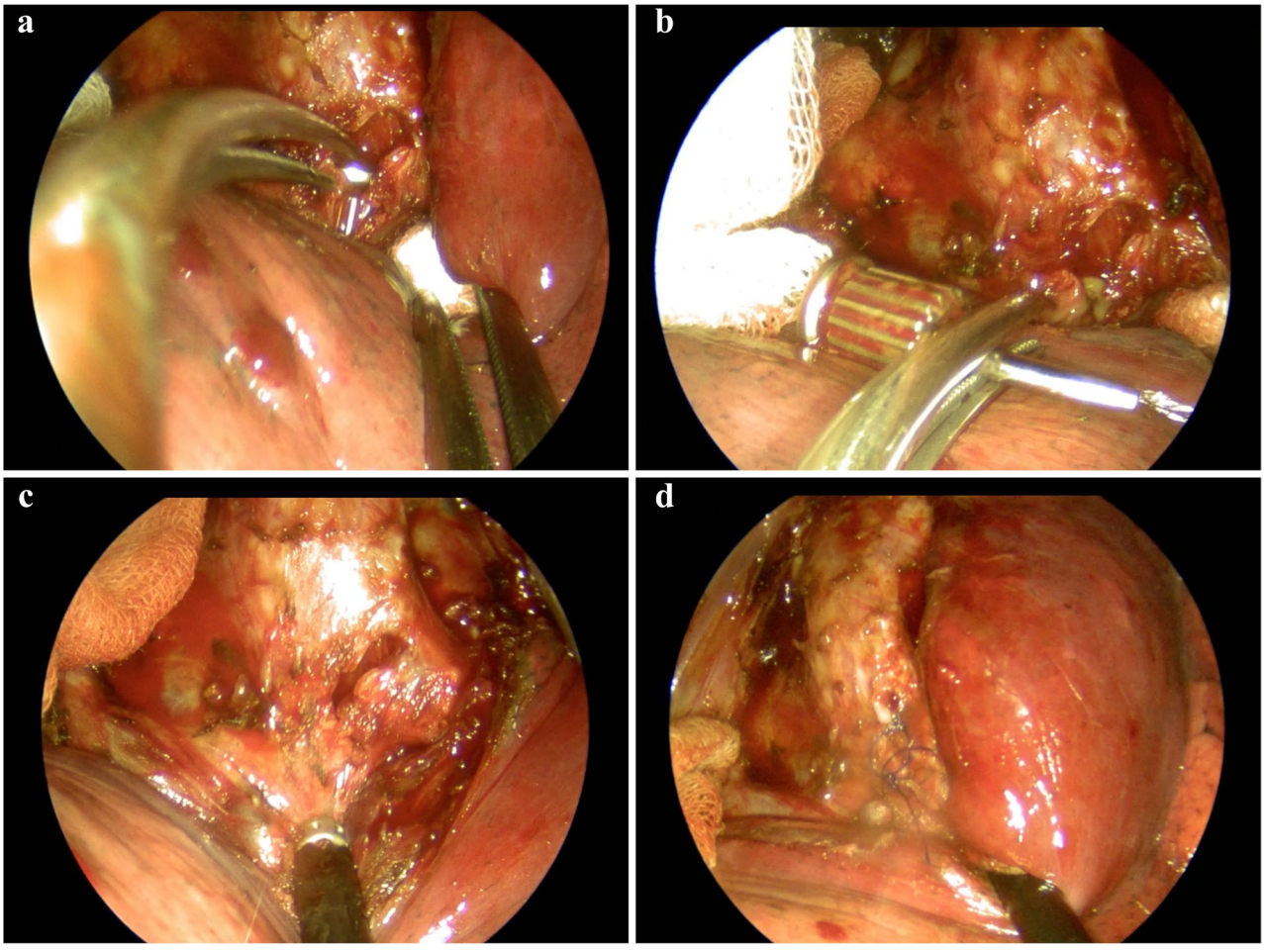

Fig. 4 **a** Bronchotomy performed on the lower lobe bronchus. **b** Retrieval of the aspirated dental implant driver. **c** Inspection of the lower lobe bronchus following removal. **d** Bronchotomy incision after closure with interrupted sutures.

of airway interventions [7, 8]. However, the success of endoscopic removal largely depends on the mobility and degree of impaction of the foreign body, and rigid bronchoscopy may fail when objects are firmly embedded in distal bronchi. In such situations, uniportal VATS represents an effective and minimally invasive alternative to thoracotomy. This approach offers excellent visualization, allows precise bronchotomy under direct control, and enables safe removal while minimizing postoperative morbidity. Reports of metallic dental instruments aspirated into the bronchial tree and managed with uniportal VATS are extremely rare, and this case further supports the role of uniportal VATS as a safe and efficient option in selected adult patients when endoscopic management is unsuccessful.

Supplementary Information

The online version contains supplementary material available at https://doi.org/10.1186/s43168-026-00529-z.

Supplementary Material 1. Video 1. Rigid bronchoscopy demonstrating the foreign body localized at the entrance of the right lower lobe bronchus.

Supplementary Material 2. Video 2. Uniportal VATS demonstrating bronchotomy at the level of the right lower lobe bronchus and the extraction of the foreign body.

Acknowledgements
The authors would like to thank the surgical team and nursing staff for their assistance in patient care.

Informed consent
Informed consent was obtained from the individual participant included in the study.

Artificial intelligence involvement
No part of this manuscript has been produced with the help of artificial intelligence software or tools.

Authors' contributions
G.B.: Conception of the case report, surgical management of the patient, manuscript drafting, and critical revision. M.Z.Ö.: Data collection, assistance in surgical management, and contribution to manuscript preparation. H.Ç.: Literature review, preparation of figures and tables, and final editing of the manuscript. T.A.: Data collection, assistance in surgical management, manuscript drafting, and critical revision.

Funding
This research did not receive any specific grant from funding agencies in the public, commercial, or not-for-profit sectors.

Data availability
No datasets were generated or analysed during the current study.

Declarations

Competing interests
The authors declare no competing interests.

Received: 5 November 2025 / Accepted: 1 February 2026
Published online: 09 February 2026

References

1. Hewlett JC, Rickman OB, Lentz RJ, Prakash UB, Maldonado F (2017) Foreign body aspiration in adult airways: therapeutic approach. J Thorac Dis 9(9):3398–3409. https://doi.org/10.21037/jtd.2017.06.137. PMID: 29221325; PMCID: PMC5708401
2. Boyd M, Chatterjee A, Chiles C, Chin R Jr (2009) Tracheobronchial foreign body aspiration in adults. South Med J 102(2):171–174. https://doi.org/10.1097/SMJ.0b013e318193c9c8. PMID: 19139679
3. Wu TH, Cheng YL, Tzao C, Chang H, Hsieh CM, Lee SC (2012) Longstanding tracheobronchial foreign body in an adult. Respir Care 57(5):808–810. https://doi.org/10.4187/respcare.01445. Epub 6 Dec 2011. PMID: 22152102
4. Jang G, Song JW, Kim HJ, Kim EJ, Jang JG, Cha SI (2022) Foreign-body aspiration into the lower airways in adults; multicenter study. PLoS ONE 17(7):e0269493. https://doi.org/10.1371/journal.pone.0269493. PMID: 35793276; PMCID: PMC9258814
5. Acharya K (2016) Rigid Bronchoscopy in Airway Foreign Bodies: Value of the Clinical and Radiological Signs. Int Arch Otorhinolaryngol 20(3):196–201. https://doi.org/10.1055/s-0036-1584293. Epub 30 May 2016. PMID: 27413398; PMCID: PMC4942294
6. Kakamad FH, Ali RK, Amin BJH, Mohammed SH, Omar DA, Mohammed KK, Karim SO, Kakamad SH, Salih RQM, Mohammed DA, Salih AM, Mustafa MQ (2023) The role of VATS in the removal of intrathoracic foreign bodies - a systematic review. Indian J Thorac Cardiovasc Surg 39(2):125–136. https://doi.org/10.1007/s12055-022-01445-9. Epub 27 Dec 2022. PMID: 36785615; PMCID: PMC9918628
7. Uluç K, Akkütük Öngel E, Köylü İlkaya N, Devran Ö, Çolakoğlu ŞM, Kutbay Özçelik H (2024) Analysis of 332 fiberoptic bronchoscopies performed in a respiratory intensive care unit: a retrospective study. Eur Rev Med Pharmacol Sci 28(4):1433–1438. https://doi.org/10.26355/eurrev_202402_35465 PMID: 38436177
8. Uluç K, Öngel EA, İlkaya NK, Devran Ö, Özçelik HK (2023) Indication, complication, and prognosis of fiberoptic bronchoscopy guided percutaneous dilatation tracheostomy opening in respiratory intensive care unit: a retrospective study. Eur Rev Med Pharmacol Sci 27(24):11771–11779. https://doi.org/10.26355/eurrev_202312_34775. PMID: 38164840

Publisher's Note

Springer Nature remains neutral with regard to jurisdictional claims in published maps and institutional affiliations.