An unusual cause of endocarditis

B. Kocazeybek, M. S. Bilal, B. Sönmez, S. Karcier, S. Küçükoğlu, D. Şener, A. Ordu, H. Çakan, A. Ayyildiz and E. Ural

Florence Nightingale Hastanesi, Mikrobioloji Laboratuvari, 80320 Çaglayan-Istanbul, Turkey

CASE 1

A 44-year-old female patient was admitted to the Cardiology Institute, Istanbul University with cardiac arrythmia and fatigue. She had been treated for mitral valve prolapse since age 28. Transthoracic echocardiography (TTE) revealed prominent prolapse of the mitral and tricuspid valves, mitral insufficiency and dilatation of the left ventricular cavity. Left ventricular ejection fraction was calculated as 70%. The patient had a history of raw milk ingestion over the last few years. One month after her initial admission, she had a body temperature of 39 °C, arthralgia and swollen knees. Despite antibiotic therapy, her fever persisted for 2–3 months, with a weight loss of about 10 kg. On transesophageal echocardiography (TEE), a 1-cm floppy mass was found on the anterior leaflet of the mitral valve (see Figure 1), which was interpreted as a vegetation.

CASE 2

A 55-year-old female patient was hospitalized in Florence Nightingale Hospital with severe back pain, leg pain and high fever. She had been an insulin-dependent diabetic for 30 years. She had previously undergone coronary angioplasty and placement of a permanent pacemaker. In addition, elevation in the erythrocyte sedimentation rate (35–75 mm/h) and irregularities of blood glucose level were detected. She had a history of ingestion of cheese made of raw milk over the last 6 months.

A provisional diagnosis was made and combination antibiotic therapy started. Subsequently, hyperemia, pain and swelling developed at the location of the permanent pacemaker with abscess formation. On TEE, a vegetation was detected in the right atrium over the permanent pacemaker lead. A 24-h holter electrocardiogram showed sinus rhythm with no need for a permanent pacemaker. The pacemaker was removed, but 11 days after the operation the patient was hospitalized again with a right-sided pleural effusion and dyspnea. A pulmonary embolism was diagnosed, and thrombus extending from the superior vena cava to the right atrium was detected with a thoracic CT scan and TEE.

Open-heart surgery with total circulatory arrest was performed; the right atrium was opened and the thrombi in the superior vena cava and right atrium were cleared. After the operation, combined antibiotic therapy was continued for 2 months.

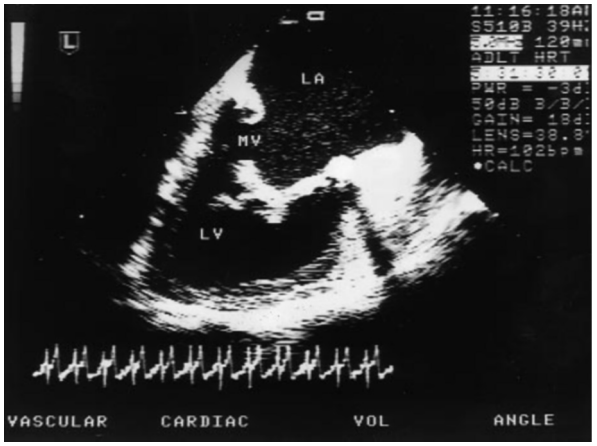

Figure 1

QUESTIONS

1. What is the diagnosis for both of these cases?
2. How would you confirm the diagnosis?
3. What are the main clinical features?
4. In both cases, what has predisposed to infection localizing in the heart?
5. What is the recommended treatment?

REFERENCES

1. Young EJ. Serologic diagnosis of human brucellosis: analysis of 214 cases by agglutination tests and review of the literature. *Rev Infect Dis* 1991; 138: 359–72.
2. al Harthi SS. The morbidity and mortality pattern of *Brucella* endocarditis. *Int J Cardiol* 1989; 25(3): 321–4.
3. Jacobs F, Abramowicz D, Vereerstraeten P, Le Clerc JL, Zech F, Thys JP. *Brucella* endocarditis; the role of combined medical and surgical treatment. *Rev Infect Dis* 1990; 12(5): 740–4.
4. Wade JS, Cobbs CG. Infections in cardiac pacemakers. In: Remington JS, Swartz MN, eds. *Current clinical topics in infectious diseases.* New York: McGraw-Hill, 1988: 44–51.

Corresponding author and reprint requests: B. Kocazeybek, Florence Nightingale Hastanesi, Mikrobioloji Laboratuvari, 80320 Çaglayan-Istanbul, Turkey
Tel: + 90 212 225 83 93
Fax: + 90 212 225 83 93

© 2000 Copyright by the European Society of Clinical Microbiology and Infectious Diseases, *CMI*, **6**, 325–327