The Egyptian Journal of Bronchology

CASE REPORT Open Access

Simple fixation methods for proximal tracheal silicone stents: experience from two cases

Güntuğ Batıhan[1*], Muhammed Ziya Öcal[1], Hatice Çetin[1] and Timuçin Alar[1]

Abstract

Background Migration is a frequent and clinically significant complication of silicone stents used in the management of benign proximal tracheal stenosis. Commercial fixation systems are available, yet they may be costly, technically demanding, or not readily accessible in many institutions. This report presents two simple, low-cost fixation techniques that were applied to stabilize proximal tracheal silicone stents, aiming to prevent migration without the need for dedicated devices.

Case Presentation Two patients with high-grade benign proximal tracheal stenosis underwent silicone stent placement. In the first patient, external stabilization was achieved using a transcutaneous fixation technique: a 16G intravenous catheter was inserted through the anterior cervical skin into the tracheal lumen, allowing passage of a Prolene® suture that was retrieved bronchoscopically and secured externally. In the second patient, the stent was stabilized using a nasal fixation technique in which a suture placed at the proximal end of the stent was exteriorized through the nasal passage with flexible bronchoscopy and anchored externally. Both procedures were completed safely, without bleeding, infection, or migration during follow-up.

Conclusions These two cases demonstrate practical, inexpensive, and reproducible alternatives for stabilizing proximal tracheal silicone stents using basic surgical materials. Such techniques may be valuable in centers where commercial fixation systems are unavailable or impractical, offering reliable solutions to prevent stent migration in benign airway stenosis.

Keywords Tracheal stenosis, Airway stents, Bronchoscopy, Stent migration, Minimally invasive surgical procedures

Background

Proximal tracheal stenosis is most often a late complication of prolonged intubation or tracheostomy [1]. When resection or reconstruction is not possible, silicone stenting provides durable airway patency, yet upward stent migration remains a recurrent issue [2]. This problem is particularly pronounced in short, compliant tracheas, where coughing and negative inspiratory forces can easily displace the device.

Several external fixation systems have been described, ranging from percutaneous sutures to complex anchoring devices [3–6]. However, many of these require specialized materials or create discomfort for the patient. The two techniques described here were developed to offer an uncomplicated, low-cost alternative that can be applied quickly in the operating room or bronchoscopy suite.

The novelty of this report does not lie in the concept of tracheal stent fixation itself, but in the simplification and low-cost adaptation of fixation techniques that can

*Correspondence:
Güntuğ Batıhan
guntugbatihan@gmail.com
[1]Department of Thoracic Surgery, Çanakkale Onsekiz Mart University, Prof. Dr. Sevim Buluç St., Çanakkale 17110, Türkiye

© The Author(s) 2026. **Open Access** This article is licensed under a Creative Commons Attribution 4.0 International License, which permits use, sharing, adaptation, distribution and reproduction in any medium or format, as long as you give appropriate credit to the original author(s) and the source, provide a link to the Creative Commons licence, and indicate if changes were made. The images or other third party material in this article are included in the article's Creative Commons licence, unless indicated otherwise in a credit line to the material. If material is not included in the article's Creative Commons licence and your intended use is not permitted by statutory regulation or exceeds the permitted use, you will need to obtain permission directly from the copyright holder. To view a copy of this licence, visit http://creativecommons.org/licenses/by/4.0/.

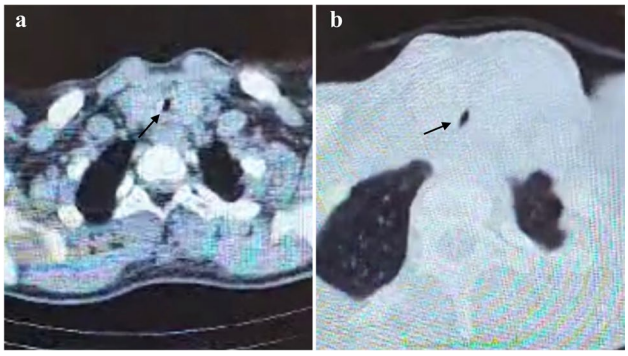

Fig. 1 (**a**) Axial computed tomography image demonstrating proximal tracheal stenosis (arrow). (**b**) Coronal computed tomography image showing the same stenotic segment at the proximal trachea (arrow), illustrating the extent and localization of airway narrowing

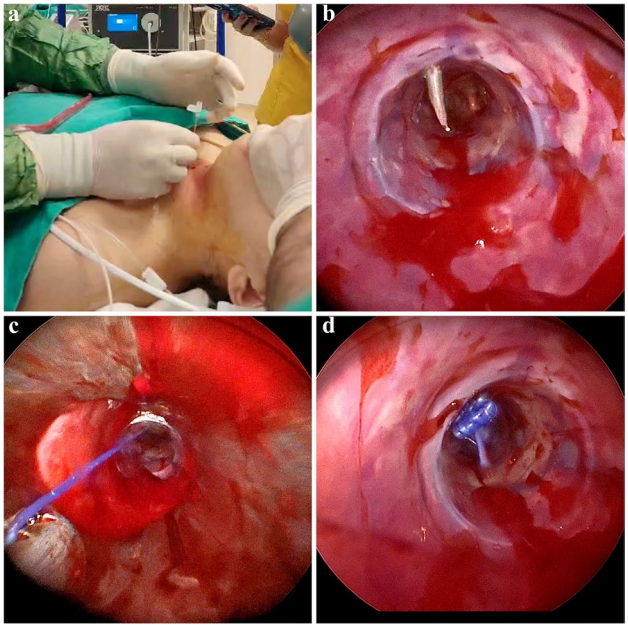

Fig. 2 (**a**) Transcutaneous access for stent fixation under sterile conditions. (**b**) Endoscopic view demonstrating intraluminal needle penetration through the tracheal wall into the silicone stent. (**c**) Passage of the fixation suture through the stent lumen under bronchoscopic guidance. (**d**) Final endoscopic appearance after completion of transcutaneous fixation, showing stable anchoring of the silicone stent

be modified according to patient-specific anatomical and clinical constraints, particularly in cases where transcutaneous fixation may be difficult or risky.

Case presentation

Case 1

A 23-year-old woman with a known history of epilepsy and prior prolonged intubation presented with symptomatic restenosis following a recent cervical tracheal resection and primary anastomosis for post-intubation tracheal stenosis. Persistent epileptic episodes likely contributed to increased airway pressure and recurrent mucosal trauma, resulting in early restenosis. She was referred with progressive dyspnea and stridor.



Fig. 3 External view demonstrating transcutaneous fixation of the tracheal silicone stent. The fixation suture is anchored directly to the cervical skin (arrow), providing external stabilization of the stent and preventing proximal migration

Recurrent high-grade cervical tracheal stenosis was confirmed by cervical–thoracic CT and flexible bronchoscopic evaluation (Fig. 1). According to the Freitag classification [7], the tracheal stenosis was classified as a high-grade concentric stenosis, with an estimated luminal narrowing of approximately 80–90%. After balloon dilatation, a straight silicone tracheal stent was inserted, and transcutaneous fixation technique was used to prevent migration.

Technique 1 – transcutaneous fixation

Under rigid bronchoscopy, a 16G catheter was passed percutaneously into the trachea, allowing a Prolene® suture to be retrieved bronchoscopically and anchored both intraluminally and externally (Fig. 2) (see Supplementary Video 1). This simple method provided secure fixation but initially caused challenges such as skin irritation and granulation tissue, issues that were later mitigated using a small plastic spacer and regular local care (Fig. 3).

The silicone stent was electively removed at the end of the fifth month. However, restenosis developed within one month following stent removal. A second surgical intervention, namely cricotracheal resection, was recommended, but the patient declined further surgery.

Consequently, a permanent T-tube was placed. The patient remains clinically stable at the most recent follow-up.

Case 2

According to the Freitag classification, the tracheal stenosis was classified as a high-grade concentric stenosis, with an estimated luminal narrowing of approximately 80–90%.

A 62-year-old man presented with progressive dyspnea and inspiratory stridor. Imaging revealed a large cervical mass causing severe extrinsic tracheal compression (Fig. 4). After multidisciplinary tumor board evaluation, a palliative airway-stabilizing intervention was planned to alleviate obstruction and establish a tissue diagnosis.

Based on the Freitag classification system, the stenosis was defined as a severe tracheal stenosis, with approximately 70–80% reduction of the tracheal lumen. Rigid bronchoscopy was performed, with a trans-tracheal biopsy obtained from the compressive lesion. Balloon dilatation was followed by placement of a straight silicone tracheal stent using the nasal fixation technique.

Technique 2 – nasal fixation

A 2 – 0 Silk suture pre-placed on the proximal stent rim was retrieved nasally using flexible bronchoscopy and secured externally with a small, soft anchoring piece (Fig. 5) (see Supplementary Video 2). This method allowed the stent to be kept in a stable position while permitting fine adjustment in case of vocal-cord–related symptoms.

The patient experienced mild foreign-body sensation but maintained adequate airway patency without stent migration. Pathology was consistent with multinodular goiter. He underwent curative resection via cervical incision and partial sternotomy. Tracheal integrity was preserved, and the stent was removed intraoperatively. At 6-month follow-up, the patient was asymptomatic with no recurrence of airway compromise.

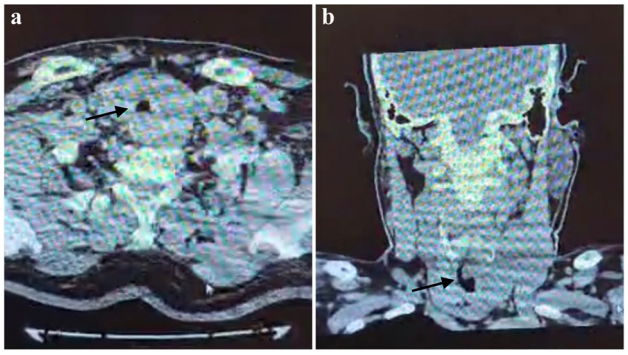

Fig. 4 (**a**) Axial computed tomography image demonstrating proximal tracheal stenosis in the second case (arrow). (**b**) Coronal computed tomography image showing the same stenotic segment (arrow), illustrating the longitudinal extent and anatomical level of the tracheal narrowing

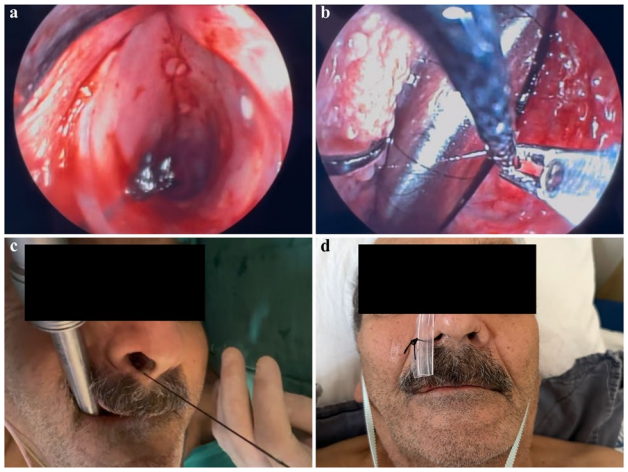

Fig. 5 (**a**) Bronchoscopic view demonstrating proximal tracheal stenosis before stent fixation. (**b**) Endoscopic view showing passage of the fixation suture through the tracheal wall and silicone stent under bronchoscopic guidance. (**c**) External view illustrating exteriorization of the fixation suture through the nasal route during nasal fixation. (**d**) Final external appearance after completion of nasal fixation, demonstrating secure anchoring of the tracheal silicone stent without direct cervical skin fixation

Conclusions

Silicone stents remain a cornerstone in the treatment of benign tracheal stenosis, yet migration continues to be one of their major limitations. Reported migration rates may reach 25%, particularly in the proximal trachea where cough dynamics and abrupt intrathoracic pressure changes destabilize the implant [2]. The problem is further pronounced in patients with short tracheas, hyperdynamic airways, or recurrent episodes of elevated airway pressure. The two simple fixation methods applied in our cases were designed as practical solutions, based on basic instruments available in most thoracic surgery and bronchoscopy units.

The transcutaneous fixation technique conceptually parallels transcervical strategies initially described by Colt and later refined by Majid, including angiocatheter-guided passage and external securing elements [3, 4]. Although generally effective, these approaches have occasionally been associated with localized cutaneous irritation or cosmetic concerns. Similar observations were reported by Huang et al. [5] in their 45-patient series, where migration was rare (6%), but granulation (20%) and limited cellulitis (6%) occurred—findings that emphasize the importance of exit-site care. In our patients, small granulation nodules were observed and successfully managed with routine cleaning and local debridement.

To minimize cutaneous pressure effects, we used a thin plastic spacer beneath the external knot—an adaptation conceptually similar to the "buried suture" approach described by Salguero et al. [8]. Other refinements in the literature include the Lichtenberger needle carrier for controlled inside-to-outside passage of sutures [9], the "double hitch stitch" technique proposed by Arbat et al. [10], and several dedicated fixation concepts reported by Miwa et al. [11]. All reflect an ongoing effort to balance stable anchoring with minimal tissue trauma. As highlighted by Martínez-Ballarín et al. [12], patient comfort, tolerance, and ease of maintenance remain essential principles—still valid today.

Clinically, transcutaneous fixation appears most useful in patients with vigorous cough reflexes, dynamic cervical airway movement, or mobile proximal tracheal segments. Nevertheless, anatomical challenges such as large thyroid volume, substernal extension, or distorted cervical planes may elevate the risk of bleeding or infection, making external anchoring less suitable. In such situations, the nasal fixation technique offers an alternative. Although nasal fixation has been reported previously, its use specifically for tracheal stenting remains poorly represented. In our practice, it provided reliable stabilization, avoided cosmetic concerns, and allowed adjustable suture tension for patients with transient swallowing discomfort or voice alteration.

Despite the natural limitations of a small series, the absence of migration and the low complication profile in our experience are encouraging. Both fixation methods offer accessible, low-cost options that may be especially valuable in centers without commercial stent-fixation systems or in resource-constrained environments. Larger comparative studies will help clarify optimal patient selection, refine technical steps, and determine long-term durability. However, based on these cases, thoughtfully applied mechanical fixation using simple materials may significantly enhance stent stability and safety in benign tracheal stenosis.

Abbreviations

CT Computed tomography

Supplementary Information

The online version contains supplementary material available at https://doi.org/10.1186/s43168-026-00533-3.

Supplementary Material 1.

Supplementary Material 2.

Authors' contributions

G.B. conceived the concept of the report, collected clinical data, performed the procedures, interpreted the patient outcomes, and was the primary contributor to the manuscript preparation. M.Z.O. contributed to the clinical evaluation of the cases, assisted in data interpretation, and reviewed the manuscript for intellectual content. H.Ç. supported the bronchoscopy procedures, contributed to intraoperative decision-making, and assisted in manuscript revision. T.A. contributed to the literature review, preparation of the figures, and critical revision of the final text. All authors read and approved the final manuscript.

Funding

No funding was received for the preparation of this case report.

Data availability

All data generated or analysed in this case report are included within the manuscript.

Declarations

Ethics approval and consent to participate

This article presents two clinical cases managed in routine practice. According to institutional and national regulations, ethics committee approval is not required for single or limited case reports that do not involve experimental protocols or research data beyond standard clinical care. Written informed consent was obtained from both patients for the publication of their clinical data and accompanying images.

Consent for publication

Written informed consent for publication of all clinical information and images was obtained from the patients involved in this case report.

Competing interests

The authors declare no competing interests.

Received: 1 December 2025 / Accepted: 6 February 2026
Published online: 13 February 2026

References

1. Kim SS, Khalpey Z, Hsu C, Little AG (2017) Changes in Tracheostomy- and Intubation-Related tracheal stenosis: implications for surgery. Ann Thorac Surg 104:964–970. https://doi.org/10.1016/j.athoracsur.2017.03.063
2. Amour J, Soummer A, Langeron O, Riou B (2004) Emergency treatment of tracheobronchial stent migration. Anesthesiology 101:1230–1232. https://doi.org/10.1097/00000542-200411000-00026
3. Colt HG, Harrell J, Neuman TR, Robbins T (1994) External fixation of subglottic stents. Chest 105:1653–1657. https://doi.org/10.1378/chest.105.6.1653
4. Majid A, Fernandez-Bussy S, Kent M, Folch E, Fernandez L, Cheng G, Gangadharan SP (2012) External fixation of proximal tracheal airway stents: a modified technique. Ann Thorac Surg 93:167–169. https://doi.org/10.1016/j.athoracsur.2012.01.094
5. Huang J, Zhang Z, Zhang T (2018) Suture fixation of tracheal stents for the treatment of upper trachea stenosis: A retrospective study. J Cardiothorac Surg 13:111. https://doi.org/10.1186/s13019-018-0790-x
6. Mehta RM, Singla A, Shah A, Loknath C (2017) The Hitch stitch: an effective method of preventing migration in high tracheal stenosis. Respiration 93:106–111. https://doi.org/10.1159/000453075
7. Freitag L, Ernst A, Unger M, Kovitz K, Marquette CH (2007) A proposed classification system of central airway stenosis. Eur Respir J. ;30(1):7–12. https://doi.org/10.1183/09031936.00132804. Epub 2007 Mar 28. PMID: 17392320
8. Salguero BD, Song KJ, Agrawal A, Chaddha U (2023) External fixation of upper tracheal stents in complex stenosis: revising the Hitch stitch. Ann Am Thorac Soc 20:1353–1356. https://doi.org/10.1513/AnnalsATS.202302-127CC
9. Salati V, Lovis A, Gonzalez M, Sandu K, Gorostidi F (2022) Novel technique for fixing tracheal stents. Ann Thorac Surg 113:393–395. https://doi.org/10.1016/j.athoracsur.2021.07.082
10. Arbat SA, Deshpande PS, Chourasia SR (2021) Double Hitch stitch is a novel technique for fixation of tracheal stent in a case of tracheoesophageal fistula: a case report. Egypt J Bronchol 15:28. https://doi.org/10.1186/s43168-021-00074-x

11. Miwa K, Takamori S, Hayashi A, Fukunaga M, Shirouzu K (2004) Fixation of silicone stents in the subglottic trachea: preventing stent migration using a fixation apparatus. Ann Thorac Surg 78:2188–2190. https://doi.org/10.1016/j.athoracsur.2003.10.085
12. Martínez-Ballarín JI, Díaz-Jiménez JP, Castro MJ, Moya JA (1996) Silicone stents in the management of benign tracheobronchial stenoses: tolerance and early results in 63 patients. Chest 109:626–629. https://doi.org/10.1378/chest.109.3.626

Publisher's note

Springer Nature remains neutral with regard to jurisdictional claims in published maps and institutional affiliations.

Güntuğ Batıhan is an Associate Professor of Thoracic Surgery with clinical and academic focus on airway surgery, minimally invasive thoracic procedures, and interventional pulmonology.